

Case Report

Two Cases of Pseudohyperkalemia that Occurred after Emergency Splenectomy: What Goes Up, Will Come Down

Tan GH, Nor Faezan AR, Hairol AO, Bong JJ

Department of General Surgery, Universiti Kebangsaan Malaysia Medical Centre, Jalan Yaacob Latif, Bandar Tun Razak, 56000 Cheras, Kuala Lumpur, Malaysia.

Abstract

Pseudohyperkalemia is a spuriously high serum potassium measurement in a patient with no clinical evidence of hyperkalemia. It has been reported to occur in patients with leukocytosis and thrombocytosis. Only a few cases of pseudohyperkalemia have been reported in patients after splenectomy. Two cases of pseudohyperkalemia occurring after emergency splenectomy for abdominal trauma are presented to highlight their clinical presentation and sequelae. Consecutive patients who underwent emergency splenectomy for trauma and subsequently developed pseudohyperkalemia were monitored in Universiti Kebangsaan Malaysia Medical Centre for their clinical sequelae. Both the patients developed leukocytosis, thrombocytosis and high serum potassium level within 2-weeks of their splenectomies. They did not demonstrate any symptoms and signs of hyperkalemia. Their conditions resolved spontaneously without any specific treatment. Pseudohyperkalemia should be suspected in a similar clinical scenario to avoid unnecessary treatment that could lead to severe hypokalemia.

Keywords: Pseudohyperkalemia, splenectomy, trauma, leukocytosis, thrombocytosis

Correspondence :

Dr Tan Guan Hee, Department of General Surgery, Universiti Kebangsaan Malaysia Medical Centre, Jalan Yaacob Latif, Bandar Tun Razak 56000 Cheras, Kuala Lumpur, Malaysia. Fax: +60391737831 Email:guanhee3479@yahoo.com

Received: Dec 29 2010 Accepted: Feb 25 2011

Introduction

Pseudohyperkalemia is a falsely high serum potassium measurement in a patient with no clinical evidence of hyperkalemia (1). This phenomenon may occur due to a variety of causes such as leukocytosis and thrombocytosis (2,3). It is important to differentiate it from true hyperkalemia. This is because an attempt to correct pseudohyperkalemia could result in severe hypokalemia. The authors report 2 consecutive cases of pseudohyperkalemia that occurred following emergency splenectomy to highlight their clinical presentation and sequelae.

Case 1

An 18-year-old man sustained blunt abdominal trauma in a road traffic accident. Clinical examination and investigations were suggestive of intra-abdominal haemorrhage. There were no other injuries noted on primary survey. An exploratory laparotomy was performed. Intra-operatively, a grade 5 splenic injury was found. Splenectomy was performed to control the bleeding. There were also a 2-cm liver laceration at segment V, and a 1-cm duodenal perforation at the anterior aspect of the first part of the duodenum (D1). The liver laceration was repaired with 2/0 prolene sutures. The D1 perforation was repaired with an

omental patch. A feeding jejunostomy tube was inserted. The intra-operative blood loss was estimated at 2L. The patient recovered well from the surgery.

He started to have leukocytosis and thrombocytosis 1-week after the operation. Their figures were highest at about day-10 post-splenectomy at $26.9 \times 10^9/L$ and $1737 \times 10^9/L$ respectively. There was no on-going sepsis at that point in time. His serum potassium level was noted to rise about 1-day before leukocytosis and thrombocytosis occurred. Incidentally, the serum potassium level normalized without any specific treatment as the leukocytosis and thrombocytosis started to resolve (Figure 1). The patient remained asymptomatic throughout. Serial electrocardiograms (ECG) of the patient were normal. A diagnosis of post-splenectomy pseudohyperkalemia was made. The feeding jejunostomy tube was removed when oral feeding was established. He was discharged from hospital 20-days after surgery. He remained well at 6-weeks follow-up in the clinic.

Case 2

A 22-year-old man was brought to the Emergency Department due to polytrauma from a motor vehicle accident. He sustained a right 7th rib fracture with pneumothorax, intra-abdominal injury and multiple long bone fractures. There were no other injuries on primary survey. A right chest drain was inserted. He was then operated on for the abdominal injury and fractures. Splenectomy was performed because there was profuse bleeding from the splenic hilum. There were deep lacerations in segment VII and VIII of the liver. The abdomen was packed to control the bleeding from these liver lacerations. The fractured right radius was plated. Both the fractured femurs were fixed with interlocking nails. He was then stabilized in the intensive care unit (ICU).

A second laparotomy was performed after 48 hours to remove the abdominal packs. There was no more bleeding or bile leakage at that time. However, he developed a biloma at day-10 post-surgery, which leaked through the laparotomy wound. The leakage was diverted away from the wound by biliary stenting and percutaneous drainage of the biloma. As a result, he did not develop any further sepsis.

He was noted to have leukocytosis and thrombocytosis starting at about 1-week post-splenectomy. Their figures peaked at $29.2 \times 10^9/L$ and $1818 \times 10^9/L$ respectively, 2-weeks after the operation. His serum potassium level rose in concordance to the increasing white cell and platelet counts. It returned to a normal level when the leukocytosis and thrombocytosis recovered, without any specific treatment (Figure 2). He was asymptomatic throughout this phase of high serum potassium readings. The serial ECG also did not show

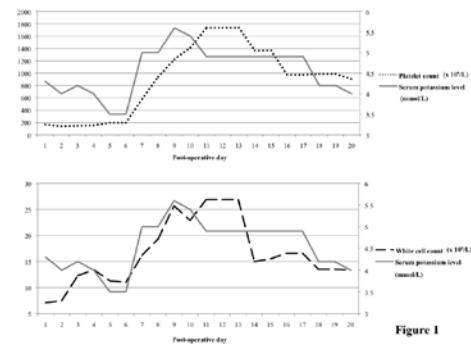


Figure 1

Figure 1: Graphs illustrating the rise and fall of serum potassium level and its association with leukocytosis and thrombocytosis in Case 1.

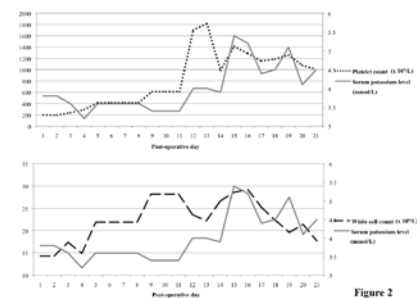


Figure 2

Figure 2: Graphs showing post-splenectomy trend of serum potassium level, white cell and platelet count of the patient in Case 2.

any changes of hyperkalemia. Therefore, he was diagnosed with post-splenectomy pseudohyperkalemia. He recovered well from the episode and was awaiting definitive management for the liver injury at a later date.

Discussion

Pseudohyperkalemia was first reported in 1955, as an increase of measured serum potassium without the clinical manifestations of electrolyte imbalance (1). This elevation results from the leakage of intracellular potassium into the extracellular fluid during in vitro clotting. Intracellular potassium could leak from cellular blood components like the erythrocytes, leukocytes and platelets (2). This phenomenon may be seen in conditions such as thrombocytosis and leukocytosis. It can also be due to improper blood taking techniques such as prolonged tourniquet time and excessive suctioning of the syringe while drawing blood (2,4).

Not surprisingly, pseudohyperkalemia is observed in several blood disorders where leukocytosis or

thrombocytosis occur. This has been reported in patients suffering from chronic myeloid leukemia (5). Another author reported spuriously high measurements of serum potassium in patients with thrombocytosis due myeloproliferative disease (6).

Splenectomy is known to cause leukocytosis and thrombocytosis (7). Post-splenectomy elevation of white cell and platelet numbers was seen in the two patients reported in this case series. Since, pseudohyperkalemia occurs in patients with leukocytosis and thrombocytosis, it is possible for it to occur in post-splenectomy patients as well. However, very few cases of pseudohyperkalemia after splenectomy have been reported in the literature. There are even fewer reported cases of pseudohyperkalemia occurring after emergency splenectomy for trauma (4). A literature search found only 3 isolated cases of pseudohyperkalemia due to emergency splenectomy (2,4).

In the two cases presented in this series, both the patients had a rise of serum potassium that coincided with the increase in white cell and platelet numbers (Figures 1,2). Since both the patients did not show any clinical evidence of hyperkalemia, a suspicion of pseudohyperkalemia was raised. The diagnosis could have been confirmed if there was a difference in the serum and plasma potassium levels (4). However, the laboratory was unfamiliar with the authors' request for plasma potassium level and the samples were rejected.

In Case 1, the serum potassium reached a peak about 1-day before the leukocytosis and thrombocytosis reached their maximum value. The serum potassium then returned to normal after the white cell and platelet counts began to reduce (Figure 1). On the other hand, the serum potassium in Case 2 only peaked a few days after leukocytosis and thrombocytosis reached their highest numbers. Its decline followed the same pattern as that in Case 1, where it normalized after leukocytosis and thrombocytosis began a downward trend (Figure 2).

From these observations, it seems that pseudohyperkalemia could occur either before or after the peak of leukocytosis and thrombocytosis. In contrast, its decline is first heralded by a reduction in white cell and platelet numbers. The incidence of pseudohyperkalemia after emergency splenectomy is unknown. It also does not affect all cases of post-splenectomy leukocytosis and thrombocytosis. The reason why it only happens to certain cases of splenectomy remains a conundrum.

Conclusion

Pseudohyperkalemia should be a differential diagnosis of a post-splenectomy patient with leukocytosis, thrombocytosis and high serum potassium. This is especially so if the patient does not have any clinical symptoms and signs of hyperkalemia. The knowledge of this condition would help avoid unnecessary treatment that could lead to potentially harmful severe hypokalemia.

References

1. Sevastos N, Theodossiades G, Archimandritis AJ. Pseudohyperkalemia in serum: a new insight into an old phenomenon. *Clin Med Res.* 2008 May;6(1):30-2.
2. Johnson CM, Hughes KM. Pseudohyperkalemia secondary to postsplenectomy thrombocytosis. *Am Surg.* 2001 Feb;67(2):168-70.
3. Ho AM, Woo JC, Kelton JG, Chiu L. Spurious hyperkalaemia associated with severe thrombocytosis and leukocytosis. *Can J Anaesth.* 1991 Jul;38(5):613-5.
4. Ahmed R, Isaac AM. Postsplenectomy thrombocytosis and pseudohyperkalemia in trauma: a case report and review of literature. *J Trauma.* 2009 Jul;67(1):E17-9.
5. Bronson WR, DeVita VT, Carbone PP, Cotlove E. Pseudohyperkalemia due to release of potassium from white blood cells during clotting. *N Engl J Med.* 1966 Feb 17;274(7):369-75.
6. Graber M, Subramani K, Corish D, Schwab A. Thrombocytosis elevates serum potassium. *Am J Kidney Dis.* 1988 Aug;12(2):116-20.
7. Park AE, McKinlay R. Spleen. In: Brunnicardi FC, Andersen DK, Billiar TR et al. *Schwartz's principles of surgery* 8th edn. New York: McGraw-Hill Professionals, 2005; 1311.