

Case report

Case Review: Post Partum Vulvo-vaginal Haematomas and Options of Management

Lim PS (✉)¹, Nirmala CK¹, Shafiee MN¹, Lim YH¹, Rozman Z², Mohd Hashim O¹, Zainul RAZ¹, Muhammad Abdul Jamil MY¹.

¹Department of Obstetrics and Gynaecology, Universiti Kebangsaan Malaysia Medical Centre, Jalan Yaacob Latif, Bandar Tun Razak, 56000 Cheras, Kuala Lumpur, Malaysia

²Department of Radiology, Universiti Kebangsaan Malaysia Medical Centre, Jalan Yaacob Latif, Bandar Tun Razak, 56000 Cheras, Kuala Lumpur, Malaysia

Abstract

Vulvo-vaginal haematomas are not an uncommon obstetric complication. Despite advances in obstetric care, practice and technique, vulvo-vaginal haematomas do occur especially in complicated vaginal deliveries. Various management options are available for vulvo-vaginal haematomas. We describe three cases of vulvo-vaginal haematomas with different severity and presentations which were managed in different manners i.e. local haemostasis control, laparotomy with hysterectomy, and transarterial embolisation. The choice of treatment options would mainly depend on the clinical presentations, availability of expertise as well as facilities. Early identification is crucial.

Keywords: Vulvo-vaginal, haematoma, post-partum haemorrhage, transarterial embolisation, balloon tamponade.

Correspondence address:

Dr Lim Pei Shan, Department of Obstetrics and Gynaecology Universiti Kebangsaan Malaysia Medical Centre, Jalan Yaacob Latif, Bandar Tun Razak 56000 Cheras, Kuala Lumpur, Malaysia.

Tel: 603-91455949 Fax: +60391456672. Email: pslim@ppukm.ukm.my , peishan9900@yahoo.com

Date of submission: 14th Dec 2010 Date of acceptance: 23rd Dec 2010 Date of publication: 6th Apr 2011

Introduction

Vulvo-vaginal haematomas is not an uncommon obstetric complication. Various management options are available and mainly depend on the severity of the clinical presentations, availability of expertise as well as facilities. We describe three cases of vulvo-vaginal haematomas with different severity and presentations which were managed in different manners.

Case report 1

A 26-year-old G2P1 at 39 weeks gestation, with previous caesarean section, was admitted in spontaneous labour. Her active phase of labour lasted

for 3 hours and her second stage lasted for 16 minutes. She delivered a baby girl with a birth weight of 3.14 kg with an estimated blood loss of 300 ml. The episiotomy wound was repaired. Five hours following delivery, she started having heavy per vaginal bleeding (4 pads fully soaked). Clinically she was pale with a blood pressure of 110/76 mmHg and pulse rate of 116 beats per minute. Her uterus was well contracted. Examination revealed a ruptured right vaginal wall haematoma measuring 7-8 cm. Estimated blood loss at this time was about one litre. She was immediately sent for an examination under anaesthesia. An active bleeder was found and haemostasis was secured with under running sutures. The total blood loss at the end of the procedure was

two litres. She required 3 units of blood. She was discharged well two days following the procedure.

Case report 2

A 33-year-old G2P1 at 40 weeks of gestation, with previous scar for breech, was admitted in the latent phase of labour with os of 2cm. She went into the second stage of labour five hours after admission and her second stage lasted for 7 minutes. She delivered a healthy baby girl weighing 3.05kg with an estimated blood loss of 250mls. The episiotomy wound was repaired. Two hours following delivery, she complained of dizziness and palpitation. She was pale with blood pressure of 80/50 mm Hg and pulse rate of 124 beats /minute. Her abdomen was soft with the uterus well contracted. There was a left vaginal wall haematoma measuring 5 x 4cm. She was resuscitated and was brought in for examination under anaesthesia. A laparotomy had to be performed due to failure of haemostasis through the vaginal route. A huge ruptured left broad ligament haematoma was noted with the blood tricking down to the vaginal wall. The bleeding was secured by hysterectomy and left internal iliac ligation. The total blood loss was almost 10 litres. She was nursed in the Intensive Care Unit post-operatively. She received a total of 16 units of blood with 4 DIVC regimes.

Case report 3

A 26 year-old para 1 had an uneventful full term vaginal delivery with episiotomy. However, she presented ten days later with left vaginal haematoma. She was transfused with 2 units of packed cells and blood products. She underwent examination under anaesthesia and 500 cc of clots were evacuated. She presented again to another centre with similar complain and was noted to have an 8X9 cm left vaginal haematoma. Despite evacuation and packing, she bled persistently and the bleeding point was not able to be localised. She was referred to our centre and a repeat examination under anaesthesia was performed. Another 150 cc of clots were evacuated and the cavity was packed with ribbon gauze. Despite the above measures, she persistently oozed and her haemoglobin dropped with evidence of deranged clotting profiles. Packed cells and blood products were given and she was referred to the interventional radiologist for transarterial embolisation. The procedure was performed through right femoral artery. A 0.035" guidewire and a 4F Cobra catheter were used. There was extravasation of contrast through the inferior vesicle branch of the posterior division of left internal iliac artery (Fig 1a,1b). Hystroacryl glue 155 was then injected. There was no

more extravasation of contrast following the embolisation (Fig 2). The patient recovered well after the embolisation and was discharged home 5 days later.

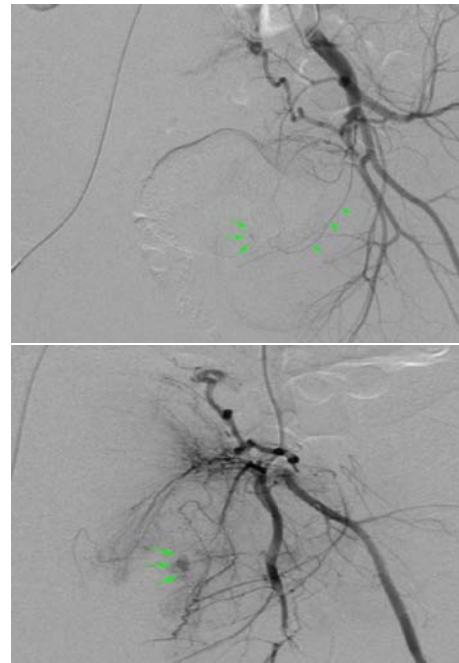


Fig 1: (a) Digital subtraction angiography (DSA) image of left internal iliac artery runs showing contrast extravasation (arrows) from the inferior vesicle branch (arrowheads) indicating an active bleed. (b) An oblique view showing more extravascular contrast accumulation in the delayed phase (arrows).

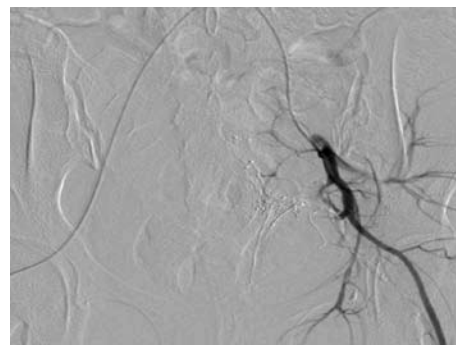


Fig 2: Post embolisation image showed blockage of the inferior vesicle artery and the bleeding was successfully arrested.

Discussion

The incidence of vulvo-vaginal haematomas ranges between 1 in 300 to 1 in 1400 deliveries (1). Despite advances in obstetric care, practice and technique. Vulvo-vaginal haematomas do occur especially in complicated vaginal deliveries. Delayed identification

or inappropriate management of vulvo-vaginal haematomas may lead to massive postpartum haemorrhage leading to potential morbidity as well as mortality. Postpartum haemorrhage remains as one of the leading cause of maternal deaths in Malaysia (2) and it accounts for nearly one-quarter of all maternal deaths world-wide (3). Therefore, prompt identification and appropriate management are crucial.

Vulvo-vaginal haematomas are often managed either conservatively or surgically. For small (<5 cm) non-expanding haematomas, with no evidence of haemodynamic instability or compromise, it may resolve by employing simple measures such as using ice packs or tight vaginal packing together with adequate analgesia (1,4). Conversely, if there is evidence of expansion or haemodynamically unstable, or compromised as illustrated in Case 1, surgical drainage under anaesthesia together with ligation of bleeders and vaginal packing are usually required following fluid resuscitation (4).

In cases that are refractory to vaginal approach, or if suspicious of broad ligament or retroperitoneal haematoma, exploratory laparotomy is traditionally the main line of treatment. Since identification of the injured vessels in a hematoma is difficult, ligation of the internal iliac artery is one of the options of management (5). Not infrequently, if these measures fail to control the bleeding and disseminated intravascular coagulopathy sets in, hysterectomy might be necessary as illustrated in case 2. Surgical approach in cases of severe post partum hemorrhage and in haemodynamically unstable or shocked state would risk the patients for a higher morbidity and mortality from anaesthetic as well as the surgical intervention itself.

In centres where facilities and expertise are available, the other option is to perform selective angiographic embolisation. It has been used as an alternative to surgical intervention for vulvo-vaginal haematoma especially in cases where there is difficulty in identifying the injured vessels as illustrated in case 3 (6,7). It can be used effectively as the primary intervention or in intractable haemorrhage following failed surgical intervention (8). Reported complications were about 6%-7% (9) include groin haematoma, puncture site infection, guidewire perforation, vaginal fistula and muscle pain. This approach has the advantage of avoidance of surgical risk, shorter hospital stay as well as preservation of fertility (10).

Recently, there were published cases where balloon tamponade had been used for vaginal haematomas or lacerations (11,12,13). The Sengstaken-Blackmore tube and Bakri tamponade balloon had been described to be effective in controlling the vaginal bleeding via compression of the bleeding points (11,12,13). The extra-advantage of the two methods is that the drainage channel allows blood loss to be estimated following insertion. It is also postulated that its usage might produce less scarring as compared to conventional vaginal packing with gauze (12). The use of balloon tamponade would be very helpful in rural area where it can be used as a temporary measure to control the bleeding while waiting for transportation to centre equipped with operating facilities. If a Bakri balloon or Sengstaken Blackmore tube is not available, a Foley catheter or condom catheter will have similar efficacy and is especially helpful in places with limited resources.

Conclusion

There are varieties of treatment options available in the management of vulvo-vaginal haematomas. The choice of the treatment options would largely depend on the clinical presentation as well as the availability of facilities and expertise. Nonetheless, early identification together with proper selection of intervention would definitely decrease the related morbidity and mortality.

References

1. Mizra FG, Gaddipati S. Obstetric emergencies. *Semin Perinatol*. 2009 Apr; 33(2): 97-103.
2. Report on the Confidential Enquires Into Maternal Deaths in Malaysia 2001-2005; 1-24. Division of Family Health Development. Ministry of Malaysia.
3. Carroli G, Cuesta C, Abalos E, Gulmezoglu AM. Epidemiology of postpartum haemorrhage: A systemic review. *Best Pract Res Clin Obstet Gynaecol* 2008 Dec;22(6):999-1012.
4. Mok-Lin EY, Laufer MR. Management of vulvar hematomas: use of a Word Catheter. *J Pediatr Adolesc Gynecol* 2009 Oct; 22(5): e156-e158.
5. Egan E, Dundee P, Lawrentschuk N. Vulvar haematoma secondary to spontaneous rupture of internal iliac artery: clinical review. *Am J Obstet Gynaecol* 2009 Jan; 200(1):e17-e18.

6. Kinishima K, Takao H, Kato N, Inoh S, Ohtomo K. Transarterial embolization of a nonpuerperal traumatic vulvar hematoma. *Radiat Med* 2008 Apr; 26(3): 168-70.
7. Vilella J, Garry D, Levine G, Glanz S, Figueroa R, Maulik D. Postpartum angiographic embolization for vulvovaginal hematoma: a report of two cases. *J Reprod Med* 2001 Jan; 46(1): 65-7.
8. Chen TH, Chen CH, Hong YC, Chen M. Puerperal pelvic hematoma successfully treated by primary transcatheter arterial embolization. *Taiwan J Obstet Gynecol* 2009 Jun; 48(2): 200-2.
9. Vegas G, Illescas T, Muños M, Pérez-Piñar A. Selective pelvic arterial embolization in the management of obstetric hemorrhage. *Eur J Obstet Gynecol Reprod Biol* 2006 Jul; 127(1): 68-72.
10. Cheng YY, Hwang JI, Hung SW, et al. Angiographic embolization for emergent and prophylactic management of obstetric hemorrhage: a four-year experience. *J Chin Med Assoc* 2003 Dec; 66(12): 727-34.
11. Tattersall M, Braithwaite W. Balloon tamponade for vaginal lacerations causing severe postpartum haemorrhage. *BJOG* 2007 May; 114(5): 647-8.
12. Yoong W, Ray A, Phillip SA. Balloon tamponade for postpartum vaginal lacerations in a woman refusing blood transfusion. *Int J Gynaecol Obstet* 2009 Sep; 106(3): 261.
13. Condie RG, Buxton EJ, Payne ES. Successful use of Sengstaken-Blackmore tube to control massive postpartum haemorrhage. *Br J Obstet Gynaecol*. 1994 Nov; 101(11): 1023-4.