

Case report

Dramatic Response of Iris and Retinal Neovascularisation Following Usage of Intravitreal Ranibizumab as Pre-operative Adjunct in Vitrectomy for Advanced Proliferative Diabetic Retinopathy

Malisa A (✉), Mae-Lynn CB

Department of Ophthalmology, Universiti Kebangsaan Malaysia Medical Centre, Jalan Yaacob Latif, Bandar Tun Razak, 56000 Cheras, Kuala Lumpur, Malaysia

Abstract

A 37-year-old Malay woman presented with progressive deterioration in vision and was diagnosed with advanced proliferative diabetic retinopathy with neovascular glaucoma. Intravitreal ranibizumab injection (an anti-vascular endothelial growth factor) was administered prior to vitrectomy. Slit lamp assessment 2 days post-injection revealed significant regression of both iris and retinal neovascularisation. This resulted in adequate reduction of intra-ocular pressure prior to surgery. In addition, the regression of retinal vessels reduced the risk of intra-operative haemorrhage, thus aiding the surgical excision of the fibrovascular membranes. Periodic post-operative assessment in the first 3 weeks showed minimal inflammation and no recurrence of vitreous haemorrhage. This case illustrates that intravitreal ranibizumab has a role as an adjunct therapy prior to diabetic vitrectomy to significantly reduce the risk of intra-ocular haemorrhage.

Keywords: Diabetic retinopathy, ranibizumab, vitrectomy, neovascularisation, vitreous haemorrhage.

Correspondence:

Dr Malisa Ami, Department of Ophthalmology, Universiti Kebangsaan Malaysia Medical Centre, Jalan Yaacob Latif, Bandar Tun Razak, 56000 Cheras, Kuala Lumpur, Malaysia

Tel no: 603-91455981

Fax: 603-91456673

Email: misha_ami@yahoo.co.uk

Date of submission: 31st Dec 2011

Date of acceptance: 10th Feb 2011

Date of publication: 6th Apr 2011

Introduction

Diabetic retinopathy remains the leading cause of blindness in the working adult population (1). Chronic elevation in serum glucose causes microangiopathy of the retinal vasculature characterised by leakage of blood constituents, abnormalities in venous calibre, microvascular occlusion and retinal ischaemia. As the ischaemia progresses, neovascularisation occurs, which is termed as proliferative diabetic retinopathy (PDR). New vessels can grow on the surface of the optic disc, the retinal vessels, the iris or the iridocorneal angle. The aqueous drains into the trabecular meshwork within the iridocorneal angle; development of new vessels here with subsequent fibrovascular membranes may impede aqueous

outflow and lead to neovascular glaucoma. As new vessels grow from the optic disc or retinal vessels, it attaches to the posterior vitreous face by means of fibrovascular tissue proliferation. Contraction of the fibrovascular tissue with or without posterior vitreous detachment may lead to tractional retinal detachment, a late complication of diabetic retinopathy (2).

The exact pathogenesis of proliferative diabetic retinopathy is still uncertain but several animal (3,4) and human studies (5,6) suggest that vascular endothelial growth factor (VEGF) plays a major role. VEGF is an angiogenic factor and a pro-inflammatory mediator, leading to neovascularisation and breakdown of the blood-retinal barrier (4,7). Ranibizumab (LucentisTM, Genentech USA) is a

recombinant humanized monoclonal antibody that binds to VEGF A and results in reduced proliferation of endothelial cells, neovascularisation and vascular leakage (8). It has been FDA-approved for use in the treatment of neovascularisation due to age-related macular degeneration (AMD) and macular oedema following retinal vascular occlusion. Following the success of anti-VEGF agents in neovascular AMD (9), research into the use of anti VEGFs in other ischaemic retinal diseases particularly diabetic retinopathy have ensued.

There are currently no published reports on the adjunctive use of ranibizumab in vitrectomy for advanced diabetic retinopathy. We report that pre-operative ranibizumab is helpful in dramatically reducing iris neovascularisation and appears to have minimised intra-operative haemorrhage during vitrectomy.

Case Report

A 37-year-old Malay woman with a 6-year history of Type 2 diabetes mellitus presented with progressive visual loss and floaters in the left eye for 2 weeks' duration. Other past medical history included hypertension and end-stage renal failure requiring haemodialysis. She was previously under the care of another ophthalmology centre for bilateral proliferative diabetic retinopathy and had 3 sessions of pan-retinal photocoagulation (PRP) for both eyes. However she had then defaulted treatment for 2 years. The visual acuity at presentation was 6/12 in the right eye and 6/36 in the left eye with no relative afferent pupillary defect. Intra-ocular pressures (IOP) measured by Goldmann tonometry in the right and left eyes were 18 and 19 mmHg, respectively. Anterior segment examination was normal. Contact gonioscopy revealed opened irido-corneal angle (Grade 4 Shaffer classification) and no neovascularisation seen. Fundus examination revealed bilateral advanced diabetic eye disease with intraretinal haemorrhages, exudates, microaneurysms, disc and retinal neovascularisation with fibrous proliferation and vitreous haemorrhage. There was presence of tractional retinal detachment involving the macula with exudative maculopathy in the left eye.

Additional bilateral PRP and left macula grid laser was given. The new vessels regressed with subsequent resolution of the vitreous haemorrhage bilaterally. Vision in the right eye improved to 6/9, however the left eye vision deteriorated to 2/60 over a one month period due to worsening of the tractional retinal detachment. Fundus fluorescein angiography

of the left eye revealed an area of ischaemia underlying the tractional retinal detachment inferiorly but no macular ischaemia. Patient was scheduled for a left trans-pars-plana vitrectomy with fibrovascular membrane dissection and excision but surgery was delayed due to an infected indwelling venous catheter which required hospital admission.

At the subsequent visit one month later during the pre-operative assessment, the vision in the left eye had further deteriorated to counting fingers. Anterior examination revealed florid iris neovascularisation (INV) with 270° angle closure (Shaffer Grade 0) in the left eye, and the IOP was elevated at 58mmHg. Fundus examination of the left eye revealed florid disc neovascularisation and tractional retinal detachment involving the macula. The IOP was lowered by topical and systemic IOP-lowering agents. After obtaining informed consent, an intravitreal injection of 0.5mg (0.05ml of 10mg/ml) ranibizumab was administered to the left eye 3 days prior to surgery. Two days after the injection, the INV and disc neovascularisation were significantly reduced. There was also worsening of the tractional retinal detachment. However, there was no conversion to rhegmatogenous component. The IOP in the left eye was controlled (12 to 15mmHg) and the angle opened up to Shaffer Grade 1 on repeat gonioscopy. A trans pars plana vitrectomy with membrane segmentation and delamination, endolaser and gas tamponade with 24% sulfurhexafluoride (SF6) was performed on day 3 post injection. Intra-operatively, there was no significant haemorrhage and the fibrovascular tissue was successfully removed within an operating time of 2 hours and 20 minutes thus flattening the retina. During the first 3 weeks post-operatively, there was minimal intraocular inflammation and the retina remained attached with no recurrence of vitreous haemorrhage. However, due to recurrence of INV and elevated IOP, the left eye vision remained poor at 2/60.

Discussion

Tractional retinal detachment and neovascular glaucoma are late complications of diabetic retinopathy and their management remains a challenge for ophthalmologists. Panretinal photocoagulation has been the standard treatment for neovascularisation, whereas vitrectomy with surgical relief of the fibrovascular traction has been successful in cases of tractional retinal detachment involving the macula (10). However, intra-operative and early post-operative vitreous haemorrhage particularly in the presence of prominent neovascularisation is a major concern. Bleeding intra-operatively obscures the surgical view

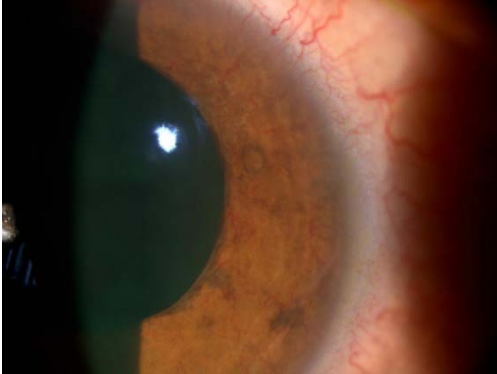


Fig1: Florid anterior segment iris neovascularisation (INV)

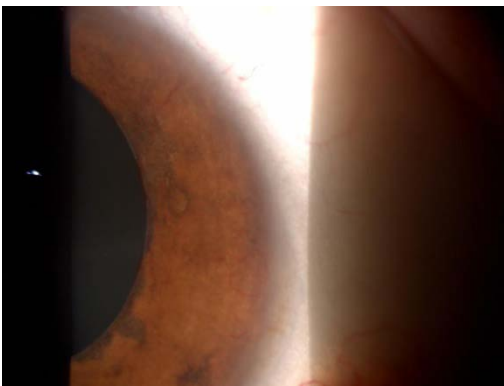


Fig 2: Regression of INV post-intravitreal ranibizumab

and potentially increases the risk of complications. Early post-operative haemorrhage can worsen inflammation, increase intra-ocular pressure, prevent detection of iatrogenic retinal breaks and possibly lead to repeat vitrectomy (11). Trials on anti-VEGF agents used as adjuncts to vitrectomy also suggest earlier resolution of vitreous haemorrhage, shorter operative time and less intra- and post-operative bleeding (12). Although, these studies used another anti-VEGF agent, bevacizumab (Avastin™, Genentech USA), presumably due to its cost, ranibizumab was used as it is designed specifically for intraocular injection. Some authors report a possible risk of worsening of the tractional retinal detachment due to contraction of the fibrovascular tissue following intravitreal injection of anti-VEGF (13).

In our case, the use of ranibizumab had resulted in considerable regression of INV and retinal neovascularisation pre-operatively. This seemed to have reduced the risk of intra-operative haemorrhage both in the anterior and posterior segments, thus facilitating the surgical dissection of fibrovascular membrane with good surgical view. Furthermore, no

significant haemorrhage occurred post-operatively. The rapid and marked beneficial effects of pre-operative intravitreal ranibizumab helped in controlling the IOP of this patient by reducing angular obstruction which has also been observed by previous researchers (14).

The emergence of anti-VEGF therapy has revolutionised the treatment of ischaemic retinal disease particularly neovascular AMD. Its usage in diabetic retinopathy seems to be promising however, the effect is temporary as in this case and can be costly. Panretinal laser photocoagulation along with good blood sugar and blood pressure control are still the mainstay of treatment. Hence, educating patients regarding diabetic retinopathy and its complications, and empowering them to take control of their disease are still strongly advocated to minimise the deleterious effects of diabetic retinopathy.

This case report is the first to illustrate the rapid and dramatic regression of INV and reduction in IOP following adjunctive intravitreal ranibizumab injection for a patient scheduled to undergo vitrectomy for advanced proliferative diabetic retinopathy. Large randomised controlled trials would need to be performed to investigate further the role of anti-VEGF in diabetic vitrectomy.

Conclusion

Pre-operative intravitreal ranibizumab is useful in rapidly inducing regression of INV leading to better IOP control and improved surgical view in subsequent vitrectomy surgery.

References

1. Klein BE. Overview of epidemiologic studies of diabetic retinopathy. *Ophthalmic Epidemiol* 2007 Jul-Aug;14(4):179-83.
2. Sun JK, Miller JW, Aiello LP. *Albert & Jakobiec's Principles and Practice of Ophthalmology-Proliferative Diabetic Retinopathy*. Philadelphia: Saunders Elsevier, 2008, 1807-9.
3. Miller JW, Adamis AP, Shima DT, D'Amore PA, Moulton RS, O'Reilly MS *et al*. Vascular endothelial growth factor/vascular permeability factor is temporally and spatially correlated with ocular angiogenesis in a primate model. *Am J Pathol* 1994 Sep;145(3):574-84.
4. Qaum T, Xu Q, Jousseaume AM, Clemens MW, Qin W *et al*. VEGF-initiated blood-retinal barrier breakdown in early diabetes. *Invest Ophthalmol Vis Sci* 2001 Sep; 42(10):2408-13.

5. Luty GA, McLeod DS, Merges C, Diggs A, Plouet J. Localization of vascular endothelial growth factor in human retina and choroid. *Arch Ophthalmol* 1996; 114(8):971-7.
6. Aiello LP, Avery RL, Arrigg PG, Keyt BA, Jampel HD *et al.* Vascular endothelial growth factor in ocular fluid of patients with diabetic retinopathy and other retinal disorders. *N Eng J Med* 1994; 331(22):1480-7.
7. Tolentino MJ, McLeod DS, Taomoto M, Otsuji T, Adamis AP *et al.* Pathologic features of vascular endothelial growth factor-induced retinopathy in the non-human primate. *Am J Ophthalmol* 2002;133(3):373
8. Lucentis (Ranibizumab) injection: Prescribing information. Website:- www.lucetis.com. Last accessed on 28/12/2010.
9. Rosenfeld PJ, Brown DM, Heier JS, Boyer Ds, Kaiser PK *et al.* Ranibizumab for neovascular age-related macular degeneration. *N Eng J Med* 2006 Oct 5; 355(4):1419-31.
10. Newman DK. Surgical management of the late complications of proliferative diabetic retinopathy. *Eye* 2010 Mar;24(3):441-9.
11. Ahmadi H, Shoeibi N, Entezari M, Monshizadeh R. Intravitreal Bevacizumab for prevention of early postvitrectomy haemorrhage in diabetic patients. *Ophthalmology* 2009 Oct; 116(10):1943-8.
12. Nicholson BP, Schachat AP. A review of clinical trials of anti-VEGF agents for diabetic retinopathy. *Graefes Arch Clin Exp Ophthalmol* 2010 Jul; 248(7):915-30.
13. Yeh PT, Yang CM, Lin YC, Chen MS, Yang CH. Bevacizumab pretreatment in vitrectomy with silicone oil for severe diabetic retinopathy. *Retina* 2009 Jun; 29(6):768-74.
14. Beutel J, Peters S, Lüke M, Aisenbrey S, Szurman *Pet al.* Bevacizumab as adjuvant for neovascular glaucoma. *Acta Ophthalmol* 2010 Feb; 88(1):103-9.