

Short correspondence/Viewpoint

The Achilles tendon: myth and true facts

Levin KB, Das S(✉)

Department of Anatomy, Faculty of Medicine, Universiti Kebangsaan Malaysia, Jalan Raja Muda Abd Aziz, 50300, Kuala Lumpur, Malaysia

Correspondence:

Dr Srijit Das, Department of anatomy, Faculty of Medicine, Universiti Kebangsaan Malaysia, Jalan Raja Muda Abd Aziz, 50300 Kuala Lumpur, Malaysia.

Tel : +60392897263

Fax: +60326989506

Email: drsrijit@gmail.com

Date of submission: 29th Dec 2010

Date of acceptance: 30th Jan 2011

Date of publication: 6th Apr 2011

In this article, we speculate the reasons behind the death of Achilles during the Trojan war. Roots of Medicine can be traced to ancient Greek history. From the Hippocrates Oath to the Achilles tendon, it all has a long story to tell. In the history of ancient Greece, Gods played an important role in their lives and the immortals existed.

According to Greek mythology, Achilles was the son of Thetis and Peleus. When Achilles was a baby, his parents were foretold that Achilles would die in a war, with an arrow injuring his foot. As a mother, Thetis did not want this to happen. So, she took Achilles to the River of Styx, held him with her thumb and index finger on his ankle, and dipped him into the river. This river was believed to confer Achilles immunity to any injury. However, the area of grip was above the water of this holy river. This area which was spared, was termed as the 'Thetis grip', It was the only area in Achilles' body that was susceptible to any injury (1).

At the age of 15 years, Achilles entered the Greek army when his father Peleus gave him his magical armor, a magic sword and a chariot led by two immortal horses. He told his mother that he would rather have a short and glorious life than a long and oblivious life as a farmer. At one point of time in the Trojan War, Nector asked Achilles to help him revenge Memnon who killed Nector's son. Achilles then killed Memnon, and the Trojans lost heart. Unknowingly, when Achilles was at the Scaean Gate, Paris shot a poisonous arrow, guided by the archer God, Apollo, which pierced Achilles' heel. Achilles' heel was the only spot on his body that was unprotected from injury. Hence, the name Achilles

heel is derived from the entire story mentioned above (1).

Anatomically, Achilles tendon is also known as the calcaneal tendon. In humans, Achilles tendon is located posteriorly. It is the largest and strongest tendon formed by the distal portion of the Gastrocnemius and Soleus muscle and inserts into the calcaneus. This tendon is about 6 inches in length. It is broad at mid calf, and gradually becomes narrower near its insertion into the calcaneus. A bursa is interposed between the insertion of the tendon and the bone. Along its lateral side, but superficial to it, lies the small saphenous vein. The Achilles' muscle reflex tests the integrity of the S1 spinal root. Interestingly, the tendon can sustain 7.7 times the body weight of an individual while running and 3.9 times the body weight while walking (2).

In the case of Achilles, the arrow must have pierced deep enough, passing through the tendinous sheath of flexor hallucis longus, to injure the posterior tibial artery and tibial nerve. In our opinion, the death of Achilles could be attributed to the profuse bleeding caused by the rupture of the posterior tibial vessels or the peroneal vessel which is located in this region (3). The arterial blood is of high pressure and massive blood loss would have lead to hypovolemic shock, which might have been the cause of death. Furthermore, since the posterior tibial vein is in very close proximity with the posterior tibial artery, chances of injuring the vein are high. Studies have shown that the formation of deep vein thrombosis is more frequent in the peroneal vein and posterior tibial vein (4). With vein injury, there is a possibility of thrombus formation. This thrombus in the deep vein might dislodge, and take its course up the Soleal and Gastrocnemius intramuscular venous plexus,

travelling to the popliteal vein, and further up to the femoral vein. Pulmonary embolism may result as a sequelae of this event and may cause death.

It cannot be undermined that the calf muscles function as the '*peripheral heart*' pumping blood against the gravity. Before the pumping starts, the veins in the calf are typically filled with 100 to 150 ml of blood to be pumped (5). This mechanism is responsible for returning 40-60% of the calf's venous volume proximally back to the heart (5). In the event that this mechanism fails due to a rupture of the vessels supplying the leg i.e. posterior tibial artery or vein, there will be impaired venous return causing heart failure. It may lead to death if no compensatory actions are taken.

Another hypothesis for Achilles' death may be the poison inflicted on the arrow, which could have entered the systemic blood circulation. This poison could have led to 'disseminated intravascular coagulation' or any inhibitory mechanism on the vascular system which might have led to the death of Achilles.

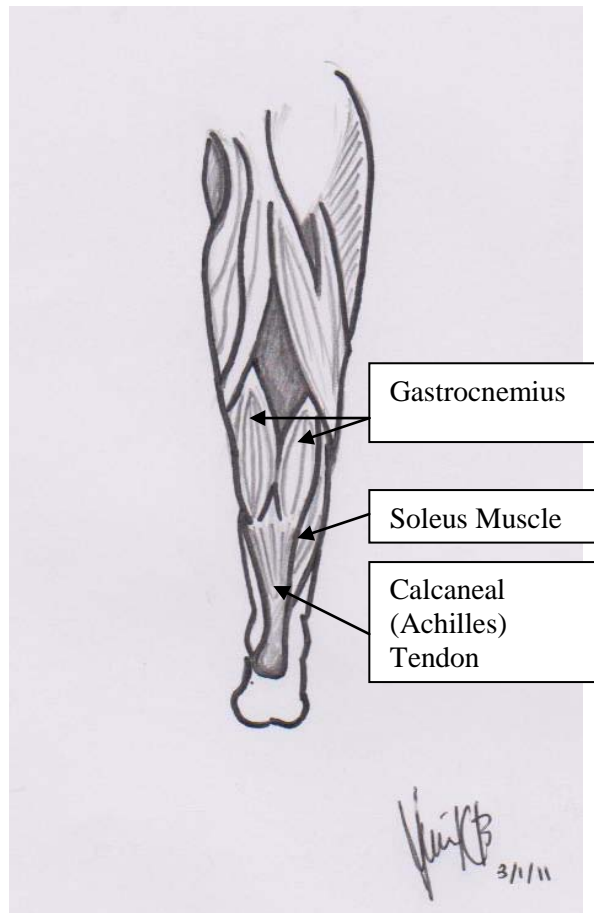


Figure 1: Posterior View of Right Leg

There could be many other reasons why an arrow pierced only into the heel of Achilles which led to his death. It would be intriguing to apply our knowledge to figure out this mystery. Admittedly, no reports are available in textbooks or in research reports. It is mere speculation on our part. The readers are left with their own guesses surrounding the death of a great warrior, Achilles. Of course, there are no prizes for guessing!

Acknowledgement:

The authors wish to acknowledge the kind help received from Tang Chao Tian.

References

1. Trojan War, <http://www.timelessmyths.com/classical/trojanwar.html#Achilles>. Last accessed on 29.12.2010.
2. Giddings VL, Beaupré GS, Whalen RT, Carter DR. Calcaneal loading during walking and running. *Med Sci Sports Exerc* 2000 Mar; 32(3): 627-34.
3. Chen TM, Rozen WM, Pan WR, Ashton MW, Richardson MD, Taylor GI. The arterial anatomy of the Achilles tendon: anatomical study and clinical implications. *Clin Anat* 2009;22 (3):377-85.
4. Labropoulos N, Webb KM, Kang SS, Mansour MA, Filiung DR, Size GP, Buckman J, Baker WH. Patterns and distribution of isolated calf deep vein thrombosis, *J Vasc Surg* 1999;30(5):787-91.
5. Kaushal (Kevin) Patel. Deep Venous Thrombosis. <http://emedicine.medscape.com/article/462390-overview>. Last accessed on 29.12.2010.