

Original Research Article

The Position of Greater Palatine Foramen in the Adult Human Skulls of North Indian Origin

Renu C

Department of Anatomy, U.C.M.S. and G.T.B. Hospital, Dilshad Garden, Delhi-110095, India.

Abstract

Dentists and Anaesthetists anaesthetize greater palatine nerve at greater palatine foramen, to perform various surgeries on hard palate. But even standard textbooks of Anatomy mention the position of greater palatine foramen in a very general way. Considering the paucity of literature on exact location of greater palatine foramen in North Indians and its variable description in standard textbooks of anatomy and anaesthesiology, following study was felt necessary to be conducted. Various parameters in relation to greater palatine foramen were noted in one hundred adult human skulls of North Indian origin. The dentition was complete with full eruption of third molar teeth. Greater palatine foramen was medial to third molar in most of the skulls seen (47.5%). Greater palatine canal opened vertically downwards in majority of the skulls examined (93.5%). Generally, the palatal vault was “U” shaped. Posterior margin of the foramen was raised in more than 63% skulls.

Keywords: Anaesthesia, dentists, greater palatine foramen, hard palate, maxillary molars

Correspondence:

Dr. Renu Chauhan, Department of Anatomy, U.C.M.S. and G.T.B. Hospital, Dilshad Garden, Delhi-110095, India. Tel: 011-22582972-74, Ext. 5106 Fax: 011-22590495 Email: renuchauhan@yahoo.com

Date of submission: 25 Feb, 2013

Date of acceptance: 2 Oct, 2013

Introduction

Dentists and anaesthetists require an accurate knowledge of the greater palatine foramen for performing posterior palatal block anaesthesia, palatorrhaphy, periodontal surgery, resection of palatal tumours, incision of palatine abscesses and various other clinical procedures. Lack of precision in the knowledge of exact position of greater palatine foramen may injure greater palatine nerves and vessels.

Majority of the anatomy textbooks mention the location of greater palatine foramen in a very casual manner e.g. the horizontal process of palatine bone contains the greater palatine foramen (1), or the greater palatine foramen lies near the lateral border of the transverse palatine suture (2). Textbooks of anaesthesiology are bit of more specific e.g. greater palatine foramen lies opposite third molar or between second and third molar (3).

Considering the paucity of literature on the exact location of greater palatine foramen and its variable description in standard textbooks of anatomy and anaesthesiology, following study was conducted to

facilitate dentists and anaesthetists prevent injury of greater palatine and vessels.

Materials and Methods

The study was conducted on hundred North Indian human skulls of both sexes. These skulls were procured from various Medical Colleges of Delhi. Only those skulls were considered for this study in which third molar had fully erupted. Divider and metric scale were used to take all the measurements.

Following observations were taken (Fig.1):

1. Situation of the foramen in relation to second and third upper molars
2. Distance from the midsagittal plane to middle of the greater palatine foramen
3. Distance from the middle of the greater palatine foramen to the posterior border of hard palate
4. Direction of opening of the greater palatine foramen on the hard palate

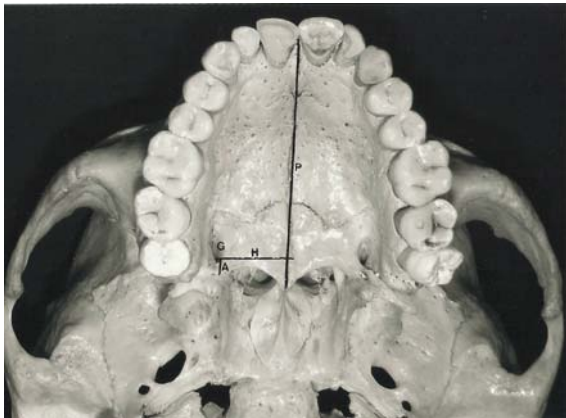


Figure 1: Illustration indicating the measurement points. P- sagittal plane, G- greater palatine foramen, H- horizontal distance from mid point of greater palatine foramen to the sagittal plane, A- vertical distance from the mid point of greater palatine foramen to the posterior border of hard palate. Palatal vault “U” shaped.

5. Presence of any bony prominence on the posterior border of the foramen
6. The shape of the palatal vault.

All these parameters were noted in accordance with the work of Westmoreland and Blaton. (4). Each reading was taken three times and their mean taken to avoid any observational bias.

Results

In the North Indian skulls examined, most common position of greater palatine foramen was found to be medial to 3rd molar (right=50, left=45) Table 1. In majority of skulls the direction of the greater palatine foramen was vertically downwards (Fig.2) (right=91, left=96) Table 2.

The palatal vault was “U” shaped in 81% of the skulls (Fig. 1, 2, 3) Table 3. The mean distance of the greater palatine foramen from the midsagittal plane was found to be 1.53 cm on the right side and 1.50 cm on the left side. The mean distance from the middle of the greater palatine foramen to the posterior border of hard palate was nearly the same on both the sides (right=0.47cm, left=0.46cm). Posterior border of the greater palatine foramen was raised in 63.64 % skulls.

Discussion

Greater palatine nerves and vessels traverse the greater palatine foramen. It is essential for the dentists and anaesthetists to know the precise location of the greater palatine who use it very often to anaesthetizing hard palate for any kind of palatal surgery e.g. anaesthetizing hard palate for periodontal procedures, drainage of abscesses and surgical procedures like dental extractions (5,6).

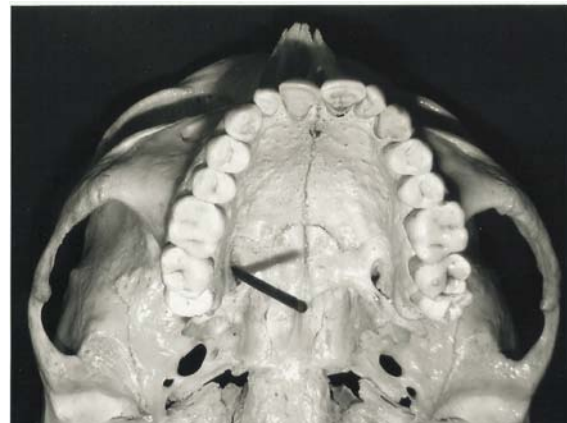


Figure 2: Probe in the greater palatine foramen showing its opening vertically downwards in the hard palate. Palatal vault “U” shaped.

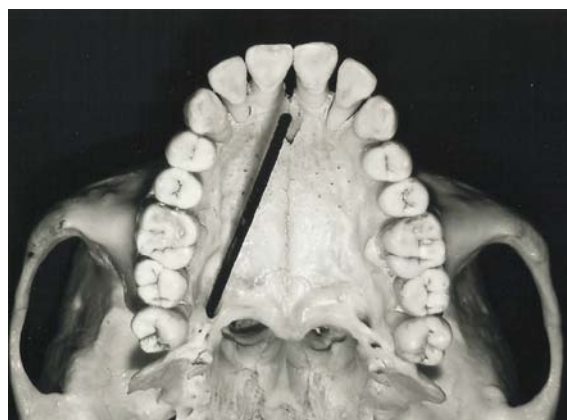


Figure 3: Probe in the greater palatine foramen showing its opening downwards and forwards in the hard palate. Palatal vault “U” shaped.

Standard text books of anatomy mention only the position of greater palatine foramen in a casual manner e.g. horizontal process of palatine bone contains greater palatine foramen near the alveolar process (1) or posterolaterally, in the hard palate are the greater palatine foramen (7) or greater palatine nerve passes through greater palatine foramen (8). Therefore, the necessity to know the exact location of greater palatine foramen.

The mean distance between the midpoints of the greater palatine foramen to the posterior border of hard palate was 0.47 cm in the skulls examined. Although, the distance varied between 0.2-0.8 cm. The mean distance from the greater palatine foramen to the posterior border of the hard palate was 0.41cm according to Wang et al. (9). This difference may be because of ethnic variation.

Our study showed that the distance from the middle of the foramen to midsagittal plane varied between 1.2-1.8 cm but in 43.18% of cases it was 1.5 cm. On the right side it was 1.53 cm and on the left it was 1.50 cm. The distance between midpoint of the greater palatine foramen and median sagittal plane

Table 1: Variation in the location of greater palatine foramen in relation to maxillary molars.

Group	Opposite 2 nd Molar	Between 2 nd and 3 rd Molar	Medial to 3 rd Molar	Behind 3 rd Molar
Right	9	23	50	18
Left	9	28	45	18
Total	18	51	95	36
Percentage	9	25.5	47.5	18

Table 2: Direction of opening of greater palatine foramen onto hard palate.

Group	Vertically downwards	Downwards and forwards
Right	91	9
Left	96	4
Total	187	13
Percentage	93.5	6.5

Table 3: Shape of the palatal vault

Shape of the palatal vault	Number out of 100	Percentage
“U”	81	81
“V”	Nil	Nil
“FLAT”	19	19

was 1.54 cm in Nigerian skulls and 1.47 cm on the right side, 1.46 on the left side in Indian skulls (10). This difference in the observation may be due to less number of Indian skulls considered in Ajmani's study, being 34 only (10). The greater palatine foramen was medial to 3rd molar in most of the skulls, 47.73%. Second most common site of greater palatine foramen was between 2nd and 3rd molar i.e. in 25% skulls. Greater palatine foramen was medial to 2nd molar in 9.1% skulls and it was behind 3rd molar in 18.18% cases. The most common (50.7%) location of greater palatine foramen was in relation IV in East Indians i.e. greater palatine foramen was lingual to third molar in them (4). This finding is different from what was observed in Chinese population. The most common position in Chinese skulls was between 2nd and 3rd molar (48%) (9).

It was observed that the greater palatine foramen was opening vertically downwards in 91% skulls (Fig.2). This finding is consistent with Westmoreland and Blanton who observed that the foramen was directed inferiorly (vertically) in 82% skulls (4). The opening of greater palatine foramen was directed anterolaterally in 38.7% of Nigerian skulls (10) which may account for occasional difficulty encountered while inserting the point of needle into greater palatine foramen and pterygopalatine canal. The direction of greater palatine foramen was downwards and forwards in 9.1% skulls only in the study conducted (Fig.3). Saralaya and Nayak observed the direction of greater palatine foramen to be forwards and medially in 46.2% skulls from South India (11). Regional variation may explain this difference.

Posterior margin of the greater palatine foramen was raised in 63.64% of skulls. Only 35.3% Indian skulls (10) and 16% of the skulls from India (4) showed the presence of bony projection along the posterior margin of the foramen. This has no clinical significance and may be due to pull of the tendon (4). A study conducted by Ajmani (10) reported that palatal vault of was U-shaped in all instances as was confirmed by this study as well that the palatal vault was “U” shaped in 77.27% skulls (Fig.1,2 and Fig.3).

References

1. Basmajian, JV, Slonecker CE. Grant's Method of Anatomy - Cervical vertebrae, Prevertebral region and Exterior of base of skull. Baltimore: Williams and Wilkins, 1989, pp 534.
2. Standaring Susan. Gray's Anatomy - The Anatomical basis of clinical practice. Philadelphia: Elsevier Churchill Livingstone, 2008, pp-414.
3. Shane SME. Principles of sedation, local and general anaesthesia in dentistry. Illinois: Charles C. Thomas, 1975, pp-173.
4. Westmoreland EE, Blanton PL. An analysis of the variation in Position of Greater Palatine Foramen in the Adult Human Skulls. Anat Rec 1982;204(4):383-388.
5. Malamed FS. Manual de anestesia local. Rio de Janeiro, 2001. pp 156-161.

6. Madeira MC. Anatomia da face. São Paulo: Sarvier, 2004, pp 204-205.
7. Moore KL and Dalley AF. Clinically oriented anatomy. Philadelphia: Lipincott Williams and Wilkins, 2010, pp-830.
8. Snell RS. Clinical anatomy by regions. Philadelphia: Lipincott Williams and Wilkins, 2012, pp-626.
9. Wang TM, Kuo KJ, Shih C, Ho LL, Lui JC. Assessment of the relative locations of the Greater Palatine Foramen in Adult Chinese Skulls. *Acta Anat (Basel)* 1988;132(3):182-186.
10. Ajamani ML. Anatomical variation in the position of the Greater foramen in the adult human skull. *J Anat* 1994; 184 (Pt 3):635-637.
11. Saralaya V, Nayak SR. The relative position of the greater palatine foramen in dry Indian Skulls. *Singapore Med J* 2007; 48(12): 1143-1146.