

Case Report

Additional Muscle in the Popliteal Fossa – a Potential Source of Entrapment of Tibial Nerve

Surekha DS, Satheesha NB (✉), Naveen K, Jyothisna P

Department of Anatomy, Melaka Manipal Medical College (Manipal Campus), Manipal University, Madhav Nagar, Manipal, Karnataka State, 576104 India.

Abstract

Popliteal fossa is a diamond shaped intermuscular space posterior to the knee joint. It contains the popliteal vessels and terminal branches of sciatic nerve, embedded in the fat. Presence of any additional muscle slips in this region can entrap/compress the nerves and vessels, leading to neurovascular symptoms. We here report the presence of an additional muscle in the popliteal fossa. The muscle had a tendinous origin from the fascia covering the popliteal vessels. The fleshy belly of the muscle was lying superficial to the popliteal vessels and the tibial nerve. The tibial nerve passed from medial to lateral side undercover of the additional muscle. The muscle had a distal tendon that merged with the medial head of the gastrocnemius muscle. It was innervated by a branch from the tibial nerve. The muscle was small and weak to cause any significant movement at the knee joint but was large enough to cause any neurovascular compression/entrapment symptoms.

Keywords: Muscle, popliteal fossa, tibial nerve, entrapment

Correspondence:

Dr. Satheesha Nayak B, Department of Anatomy, Melaka Manipal Medical College (Manipal Campus), Manipal University, Madhav Nagar, Manipal, Karnataka State, 576104 India. Tel: +91 820 2922519 / +91 9844009059 Fax: +91 820 2571905 Email: nayaksathish@yahoo.com

Date of submission: 22 Feb, 2013

Date of acceptance: 17 May, 2013

Introduction

The popliteal fossa is a diamond shaped inter-muscular space situated at the back of the knee. The fossa is very prominent when the knee joint is flexed. It contains a pad of fat, embedded in which are the popliteal vessels, small saphenous vein, common peroneal and tibial nerves, posterior cutaneous nerve of the thigh and lymph nodes. The fossa is bounded superolaterally by the biceps femoris and inferolaterally by the lateral head of the gastrocnemius and plantaris. Superomedially it is bounded by the semitendinosus and semimembranosus muscles and inferomedially by the medial head of the gastrocnemius (1).

The tibial nerve (TN) is the larger terminal branch of the sciatic nerve. It runs vertically downwards through the popliteal fossa with the popliteal artery, passing

between the two heads of gastrocnemius. The TN supplies all muscles in the posterior compartment of the leg and ends under the flexor retinaculum by dividing into the medial and lateral plantar nerves (2).

Case Report

During the routine dissections for medical undergraduate students, we found an anomalous muscle in the popliteal fossa in a male cadaver aged approximately 50-60 years. The variation was unilateral. The muscle originated as a tendon from fascia covering the popliteal vessels. The fleshy belly of the muscle was lying superficial to the popliteal vessels and the TN (Fig. 1 & 2). The TN passed from medial to lateral side undercover of the additional muscle. The muscle had a distal tendon that merged with the medial head of the gastrocnemius muscle. The tendon of origin was 2.5 cm long and the tendon of insertion was 1.5 cm

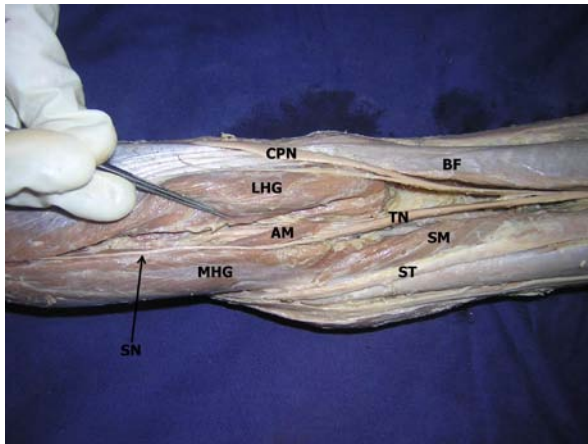


Figure 1: Dissection of the left popliteal fossa showing the additional muscle. (BF–biceps femoris; SM–semimembranosus; TN–tibial nerve; ST–semitendinosus; CPN–common peroneal nerve; LHG–lateral head of gastrocnemius; AM–additional muscle; MHG–medial head of gastrocnemius; SN–sural nerve).

long. The fleshy part of the muscle was 6.5 cm long. The circumference of the muscle was 3.5 cm. This anomalous muscle derived the nerve supply from the TN and the blood supply from the popliteal artery.

Discussion

Presence of any additional muscle slips in the popliteal fossa can entrap/compress the nerves and vessels, leading to neurovascular symptoms. In present case we report the presence of an additional muscle arising from the fascia covering the popliteal vessels. Such anomalous muscle can cause the compression of TN since it crossed superficial to the nerve. The TN can get entrapped anywhere along its course. The most common point of its entrapment is distal to the ankle (3). It can even get entrapped above the ankle. There are reports on its compression by tendinous arch of soleus and baker's cysts (4).

Muscular variations are mainly due to genetic predispositions. Most of them are due to the errors in embryologic development timings (5). Variations among the muscles of the popliteal fossa are uncommon. Somayaji et al. (6) reported an anomalous muscle in the popliteal fossa originating by 2 thin tendinous slips, one from biceps femoris and the other from semitendinosus and inserting into the tendocalcaneus. According to the reports by Barry and Bothroyd (7), if there are extra slips of origin associated with gastrocnemius and soleus muscles, they usually join the tendocalcaneus. Gupta & Bhagwat (5) reported the presence of abnormal muscular tissue in the popliteal fossa close to its roof.

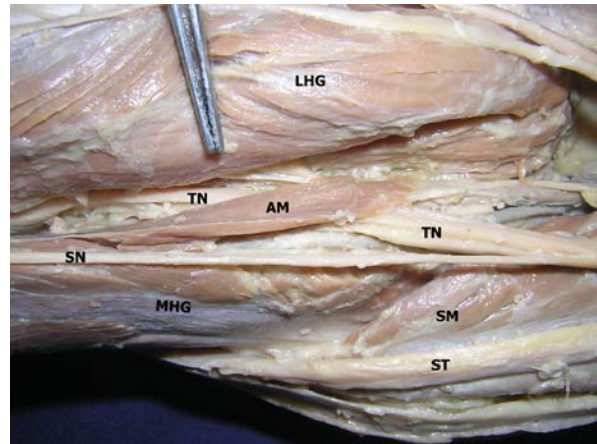


Figure 2: Closer view of the additional muscle in the popliteal fossa. (SM–semimembranosus; TN–tibial nerve; ST–semitendinosus; LHG–lateral head of gastrocnemius; AM–additional muscle; MHG–medial head of gastrocnemius; SN–sural nerve).

The gastrocnemius frequently possesses an additional head which is known as the third head of gastrocnemius (8). Presence of the third head is one of the most common variations of this muscle. The third head may arise from the long head of biceps femoris or from more than one location. In some cases it divides near its insertion to join both head of gastrocnemius (9). The third head may cause problems to the structures in the popliteal fossa by compressing them (10).

The tibial nerve can be compressed by internal neural factors or the external factors like abnormal muscles or ligaments (3). Entrapment of the TN can produce pain in the calf muscles and a considerable degree of weakness in the plantar flexion of the foot and toes. The motor deficits may be accompanied by the sensory deficits too.

Conclusion

The muscle that we reported might cause compression/entrapment of the tibial nerve. It might help the flexors of the knee in flexion of the knee and along with gastrocnemius it can even help in the flexion of the ankle. The surgeons releasing tibial nerve entrapments must be aware of possibility of such a muscle. The possible entrapment of the TN should be considered in any pain that occurs in its distribution due to suspected entrapment.

References

1. Snell RS. Clinical Anatomy. 8th Ed., Baltimore: Lippincot William and Wilkins, 2008, pp-600.

2. Standring S. Gray's Anatomy-The Anatomical Basis of Clinical Practice. 40th(Ed.). Edinburg, Churchill & Livingstone, 2008, pp-1504.
3. Reichner DR, Evans GRD. Tibial and common peroneal nerve compression in the popliteal fossa: a case report and literature view. *The Internet Journal of Plastic Surgery* 2004; 2: 1.
4. Sansone V, Sosio C, da Gama Malcher M, de Ponti A. Two cases of tibial nerve compression caused by uncommon popliteal cysts. *Arthroscopy* 2002;18(2):E8
5. Gupta RK, Bhagwat SS. An anomalous muscle in the region of the popliteal fossa: A case report. *J Anat Soc Ind* 2006; 55(2): 65-68.
6. Somayaji SN, Vincent R, Bairy KL. An anomalous muscle in the region of the popliteal fossa: case report. *J Anat* 1998; 192(pt 2): 307-308.
7. Barry D, Bothroyd JS. Tensor fasciae suralis. *J Anat* 1924; 58(pt 4): 382-383.
8. Bergman RA, Walker CW, El-Khoury GY. The third head of the gastrocnemius in CT images. *Ann Anat* 1995; 177(3): 291-294.
9. Williams PL, Bannister LH, Berry MM, Collins P, dyson M, Dussek JE, Ferguson MW. Haemolymphoid system In: Gray's Anatomy. 38th Edition, ELBS with Churchill Livingstone, Edinburgh, London. 1995, pp-1423-1431.
10. Frey H. Musculus gastrocnemius tertius. *Gegenbaurs Morphol* 1919; 50: 517-530.