

Case Report

Videolaryngoscope-Assisted Fibreoptic Tracheal Intubation in a Young Adolescent with Hunter Syndrome for Posterior Cervical Fusion

Zabir AF¹ (✉), Frawley G^{2,3}, Squire P²

¹Department of Anaesthesiology and Intensive Care, Universiti Kebangsaan Malaysia Medical Center, Jalan Yaacob Latif, Bandar Tun Razak, 56000 Cheras, Kuala Lumpur, Malaysia.

²Department of Paediatric Anaesthesia and Pain Management, Royal Children's Hospital, Melbourne, Australia.

³Anaesthesia Research Unit, Murdoch Children's Research Institute, Melbourne, Australia.

Abstract

We here describe a videolaryngoscope assisted fibreoptic tracheal intubation in a 17-year-old patient with Hunter Syndrome (Mucopolysaccharidosis Type II) and known difficult intubation who required posterior cervical fusion surgery for cervical canal stenosis. The patient had a history of failed nasal and oral fibreoptic intubation. The use of a videolaryngoscope enabled continuous visualization of the tracheal inlet and allowed a straightforward nasal fibreoptic intubation attempt without complications. This report suggests a viable alternative for the management of a known difficult airway in children with mucopolysaccharidosis.

Keywords: Mucopolysaccharidosis II, enzyme replacement therapy, anesthesia, neurosurgery, laryngoscopy, intubation

Correspondence:

Dr. Azmil Farid Zabir. Department of Anaesthesiology and Intensive Care, Universiti Kebangsaan Malaysia Medical Center, Jalan Yaakob Latif, Kuala Lumpur, Malaysia. Tel: +603 91455783 Fax: +603 91456585 Email: afzabir@gmail.com

Date of submission: 16 Apr, 2013

Date of acceptance: 5 July, 2013

Introduction

Children with Mucopolysaccharidosis (MPS) represent a number of significant anaesthetic challenges (1, 2). The deposition of glycosaminoglycans (GAG) in the soft tissue of the oropharynx has been associated with difficult airway management and obstructive sleep apnoea. Cervical canal narrowing from GAG deposition in the posterior longitudinal ligament and odontoid hypoplasia makes neck extension hazardous (3). Fibreoptic intubation may be impossible in the setting of extensive nasopharyngeal GAG deposition. The Glidescope videolaryngoscope (Verathon Medical, Sydney, Australia) has been described in children with MPS and the authors have commented that whilst an excellent view can be achieved, passage of endotracheal tube (ETT) into the larynx can be difficult (4).

Awake fibreoptic bronchoscope (FOB) tracheal intubation may not be a feasible option in the paediatric and adolescent patients with known difficult airway. The FOB technique when performed while the patient is asleep is a potential alternative but carries the risk of airway obstruction, desaturation, epistaxis and aspiration. Oral secretions and bleeding from the nasal cavity may occlude the view on the FOB. The Glidescope's angulated blade improves the Cormack-Lehane view without excessive neck movement but does not ensure tracheal intubation. Using the Glidescope to lift the tongue may achieve a clear airway and facilitate the identification of anatomical landmarks. However, the problem lies in manoeuvring the tip of the endotracheal tube though the vocal cords despite the good view.

We propose a combined technique in which the Glidescope prevents upper airway occlusion during anaesthesia and allows a clear view of the larynx during intubation whilst the ETT is guided into the trachea with the FOB. The combination of both instruments provided a reliable and quick view of the laryngeal inlet and the maneuverability to pass the ETT through the vocal cords into the trachea.

Case Report

A 17-year-old boy with attenuated Hunter syndrome (Mucopolysaccharidosis Type II) presented for decompressive cervical laminectomy and instrumented posterior cervical spine fusion. MRI demonstrated severe craniocervical compression from the odontoid tip to the C5 vertebral level with effacement of cerebrospinal fluid (CSF) surrounding the spinal cord opposite the C5-C7 vertebral bodies. Respiratory function testing reported normal spirometry (FEV1 2.13, FER 94%) and mild obstructive sleep apnoea (RDI 3.5/hr, Arousal index 11.8/hr AHI 9) on polysomnography. The patient was started on weekly recombinant idursulfase (Elaprase) enzyme replacement therapy from 13 years of age. His parents reported significant improvement especially with reduced upper airway obstruction, better mouth opening and reduced tongue size.

Previous anaesthetics for adenotonsillectomy and nasal polypectomy at 11 years of age were uneventful. In 2009 he underwent bilateral hemiepiphyodesis for genu valgum. Despite having good mouth opening, optimal positioning and anterior laryngeal pressure, a Cormack-Lehane Grade 4 laryngoscopic view using a McCoy laryngoscope was noted. Nasal fibreoptic intubation was unsuccessful due to excessive nasopharyngeal tissue and secretions. Both, a size 3 classical laryngeal mask (cLMA) and a size 3 Fastrach LMA failed to relieve upper airway obstruction. A size 4 cLMA was inserted which allowed adequate ventilation and oxygenation. Despite attempts by 2 senior paediatric anaesthetists, a size 6.0 ETT loaded on a fibreoptic bronchoscope could not be maneuvered through the size 4 cLMA presumably due to the presence of tracheal glycosaminoglycan (GAG) deposits. A patent airway allowed surgery under general anaesthesia using the size 4 cLMA.

On assessment at the Pre-Admission Anaesthetic Clinic, he weighed 68kg. His Mallampati score was 3, thyromental distance was 7cm and his anterior inter-incisor distance was 4cm. He had a large tongue and very restricted neck extension. Airway management options discussed included awake oral fiberoptic intubation, with the possible use of an LMA-Fastrach

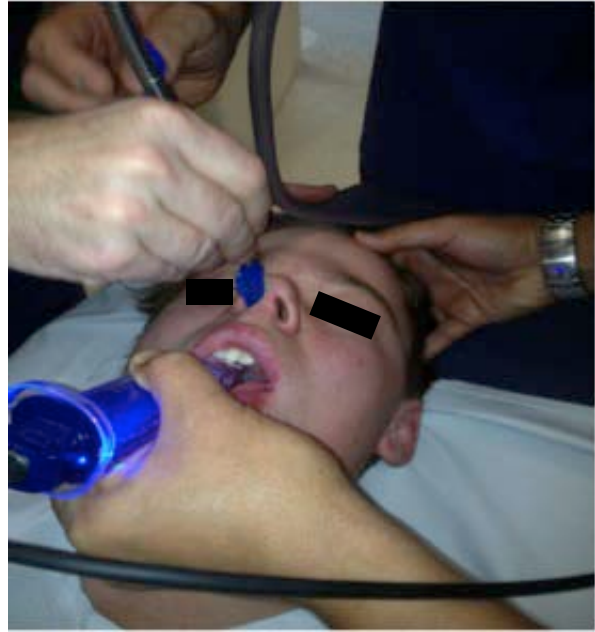

Figure 1: Glidescope assisted fibreoptic intubation

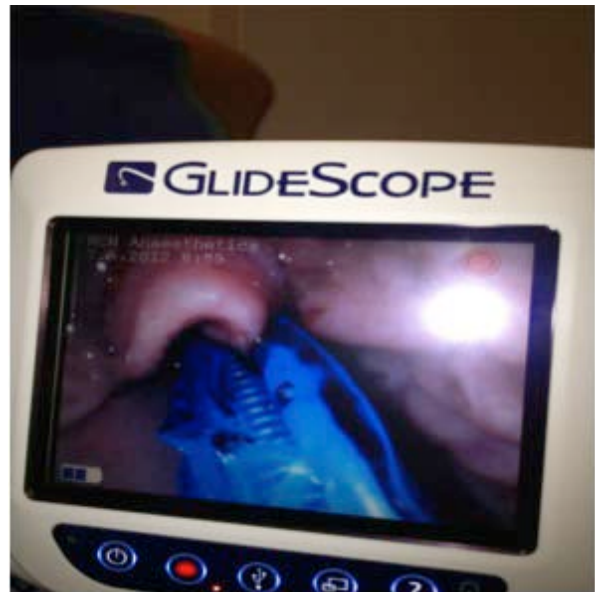


Figure 2: Laryngeal inlet visualization from the Glidescope monitor

(PacMed, Melbourne, Australia) as a backup plan. The option of a surgical airway was a last resort. The patient's preference was to be anesthetized or at least be deeply sedated for the fiberoptic intubation procedure.

On the morning of surgery it was decided that the patient would not fully co-operate with an awake oral fibreoptic intubation and nasal fibreoptic intubation

after initiation of general anaesthesia was more appropriate. An ENT surgeon was available within the theatre complex. Initial airway management involved topicalization of the airway with nebulized lignocaine 4% for three minutes. An 18-gauge intravenous (IV) cannula was inserted and IV midazolam 2mg and dexamethasone 0.15mg/kg-1 was given. Anaesthesia was induced with incremental 2-8% sevoflurane in oxygen/nitrous oxide mixture and maintained with 1.2 MAC sevoflurane (2.5%). We were able to maintain the airway with bag mask ventilation. Nitrous oxide was discontinued and preoxygenation with 100% oxygen started. Co-phenylephrine spray (0.5% phenylephrine and 5% lignocaine) was applied to each nostril. A deeper anaesthesia plane was obtained with IV remifentanyl 0.1mcg/kg/min and bolus of propofol 40mg.

As the patient was to be placed prone during cervical laminectomy, a nasal ETT was considered essential as a greater degree of adhesion of tapes is possible. A size 3 blade Glidescope allowed a full glottic view with minimal external laryngeal pressure (5). A 3.5mm intubating FOB loaded with a reinforced size 7.0 ETT was inserted through the left nostril. The ETT was passed into the trachea at the first attempt. Gentle rotation of the ETT bevel was required to slide the ETT possibly due to tracheal irregularity or the presence of glycosaminoglycan deposits within the trachea. Anaesthesia was maintained with propofol, remifentanyl and atracurium infusions. Surgery proceeded in the prone position and took 240 minutes. The patient was extubated in theatre at the end of surgery with a nasopharyngeal airway inserted. It was felt that prolonged intubation would risk increased airway oedema and that extubation at this time would occur with the most experienced and skilled anaesthetists available to handle airway complications. Extubation and recovery from anaesthesia was uncomplicated.

Discussion

Mucopolysaccharidoses (MPS) are lysosomal storage disorders categorized by deficiencies of 11 different lysosomal enzymes required for the catabolism of glycosaminoglycans. Hunter syndrome or MPS II is an X-linked recessive disorder of metabolism involving the enzyme iduronate-2-sulfatase. Combinations of upper airway infiltration of glycosaminoglycans, enlarged tongue, short immobile neck and limited mobility of the cervical spine and temporomandibular joints have significant anaesthetic implications. Difficult mask ventilation and difficult intubation are common in MPS II and the incidence increases with age (1). Within 2 months of starting recombinant

enzyme therapy, patients with MPS II normalize urinary glycosaminoglycan excretion and within six months pulmonary function tests and 6 minute walk tests improve. Most of the functional improvement occurs in the first 12-18 months of treatment but when started late in the clinical course there is little reduction in the incidence of difficult intubation.

This patient had numerous predictors of difficult airway management including large tongue, small mandible, limited mouth opening, restricted neck movement, obstructive sleep apnoea and a history of failed intubation attempts. Endotracheal intubation is essential for spine surgery in the prone position. The use of a supraglottic airway as either a primary airway device or as a conduit to oral fiberoptic intubation has been recommended but also has a significant failure rate (6). Awake fiberoptic intubation (FOI) is considered the gold standard of airway management but may be difficult in young children with Hunter syndrome, in older children with extensive nasopharyngeal GAG deposits or those with significant central nervous system disease (7). Fiberoptic intubation in children with known difficult airways has a reported failure rate of 4.5% (7). This technique is difficult or may be impossible in patients with significant glycosaminoglycan nasopharyngeal deposits and restricted upper airway patency. The view may be completely obstructed from bleeding or profuse oral secretions. Whilst dexamethasone may be of benefit in reducing mucosal oedema, the role of anticholinergics is unclear in the setting of underlying myocardial involvement in Hunter syndrome.

The Glidescope videolaryngoscope allows a 60° blade angulation and significantly improves glottic view. However, Cooper et al. (8) reported failure to intubate in 26 of 722 patients (3.7%) using the Glidescope. In the majority of these cases, failure occurred due to inability to direct the ETT into the trachea despite Cormack-Lehane 1 or 2 views. A two person laryngoscope-assisted orotracheal FOB intubation has been described (9) but not in children with known difficult intubation. The laryngoscope increases the oropharyngeal space and guides the FOB to the point where the glottis can be visualized by the FOB operator. Greib et al. (10) successfully intubated 16 adults with a combination of Storz videolaryngoscope and FOB (Karl Storz, Tuttlingen, Germany). The steep angulation of the glidescope significantly improves glottic visualization but occasionally makes ETT placement difficult. Several solutions have been proposed to solve this problem including the use of different types of stylets (11) or a transillumination device (12) in combination with a glidescope. The additional flexibility a FOB provides offers significant

advantages over rigid lighted stylets (13). Xue et al. have reported the use of the Glidescope-FOI combination for awake tracheal intubation in 13 adults (14).

The videolaryngoscope assisted FOI technique has advantages in a child with preexisting myelopathy from deposition of GAGs in the posterior longitudinal ligament. In particular the technique reduces flexion at the atlanto-axial joint during intubation. Both the Glidescope and FOB are associated with less movement at C1, 2 than the Magill laryngoscope but the movement associated with simultaneous use of both devices has not been reported (15).

The disadvantages of this technique include the need for two experienced anaesthetists and the cost of the two airway devices. Whilst the risk of epistaxis during FOI is reduced by the guided technique it is still present and may cause impairment of both oxygenation and ventilation leading to abandonment of the procedure.

Conclusion

Patients with known difficult airways constitute a major and challenging aspect of paediatric anesthesia practice. The development of newer airway devices such as the videolaryngoscopes has contributed to advances in management of such patients. In this report we described successful combination of the Glidescope and FOB in managing a known difficult airway scenario.

References

1. Frawley G, Fuenzalida D, Donath S, Yaplitto-Lee J, Peters H. A retrospective audit of anesthetic techniques and complications in children with mucopolysaccharidoses. *Paediatr Anaesth* 2012;22(8):737-744.
2. Walker R, Belani KG, Braunlin EA, et al. Anaesthesia and airway management in mucopolysaccharidosis. *J Inher Metab Dis* 2013;36(2):211-219.
3. Wraith JE, Scarpa M, Beck M, et al. Mucopolysaccharidosis type II (Hunter syndrome): a clinical review and recommendations for treatment in the era of enzyme replacement therapy. *Eur J Pediatr* 2008;167(3):267-277.
4. Theroux MC, Nerker T, Ditro C, Mackenzie WG. Anesthetic care and perioperative complications of children with Morquio syndrome. *Paediatr Anaesth* 2012;22(9):901-907.
5. Swann AD, English JD, O'Loughlin EJ. The development and preliminary evaluation of a proposed new scoring system for videolaryngoscopy. *Anaesth Intensive Care* 2012;40(4):697-701.
6. Busoni P, Fognani G. Failure of the laryngeal mask to secure the airway in a patient with Hunter's syndrome (mucopolysaccharidosis type II). *Paediatr Anaesth* 1999;9(2):153-155.
7. Blanco G, Melman E, Cuairan V, Moyao D, Ortiz-Monasterio F. Fiberoptic nasal intubation in children with anticipated and unanticipated difficult intubation. *Paediatr Anaesth* 2001;11(1):49-53.
8. Cooper RM. Use of a new videolaryngoscope (GlideScope) in the management of a difficult airway. *Can J Anaesth* 2003;50(6):611-613.
9. Kanaya N, Nakayama M, Seki S, Kawana S, Watanabe H, Namiki A. Two-person technique for fiberscope-aided tracheal intubation in a patient with a long and narrow retropharyngeal air space. *Anesth Analg* 2001;92(6):1611-1613.
10. Greib N, Stojeba N, Dow WA, Henderson J, Diemunsch PA. A combined rigid videolaryngoscopy-flexible fiberoptic intubation technique under general anesthesia. *Can J Anaesth* 2007;54(6):492-493.
11. Aucoin S, Vlatten A, Hackmann T. Difficult airway management with the Bonfils fiberscope in a child with Hurler syndrome. *Paediatr Anaesth* 2009;19(4):421-422.
12. Lane A, Lewis G. Combined use of a videolaryngoscope and a transilluminating device for intubation. *Can J Anaesth* 2007;54(7):589-590.
13. Vitin AA, Erdman JE. A difficult airway case with GlideScope-assisted fiberoptic intubation. *J Clin Anesth* 2007;19(7):564-655.
14. Xue FS, Li CW, Zhang GH, et al. GlideScope-assisted awake fiberoptic intubation: initial experience in 13 patients. *Anaesthesia* 2006;61(10):1014-1015.

15. Wong DM, Prabhu A, Chakraborty S, Tan G, Massicotte EM, Cooper R. Cervical spine motion during flexible bronchoscopy compared with the Lo-Pro GlideScope. *Br J Anaesth* 2009;102(3):424-430.