

## Case Report

# Trifurcated Hepatic Artery Proper with Unusual Course and Termination of Right Hepatic Artery into Fossa for Gall Bladder

Naveen K, Jyothsna P (✉), Swamy RS, Anitha G, Surekha D S, Ashwini AP, Satheesha NB

Department of Anatomy, Melaka Manipal Medical College (Manipal Campus), Manipal University, Manipal, Karnataka, 576104, India.

### Abstract

Variant vascular pattern affecting the hepatic artery is well documented. We here report a case of trifurcated hepatic artery proper associated with abnormal course, branching and termination of right hepatic artery. In this case hepatic artery proper trifurcated into right, middle and left branches about 2 cm before reaching porta hepatis. Left and middle branches entered the liver through the porta hepatis as normal but, the right hepatic artery took an unusual course towards the fossa for gall bladder and passed between portal vein behind and common hepatic duct, anteriorly. Just before its termination, it gave an additional hepatic branch to the liver and a cystic branch to the gall bladder. The rare course, branching pattern and abnormal termination of the right hepatic artery as reported here are vulnerable to damage during intraoperative procedures if not carefully observed. Hence prior knowledge of its variant anatomy is imperative during segmental resection of the liver and any intraoperative procedures performed in this region.

**Keywords:** Right hepatic artery, fossa for gall bladder, middle hepatic artery, variation

### Correspondence:

Jyothsna Patil, Department of Anatomy, Melaka Manipal Medical College (Manipal Campus), Manipal University, Manipal, Karnataka, 576104, India. Tel: +919449637003 Fax: 91-820-2571905 Email: patiljyothsna@gmail.com

Date of submission: 10 Oct, 2013

Date of acceptance: 18 Mar, 2014

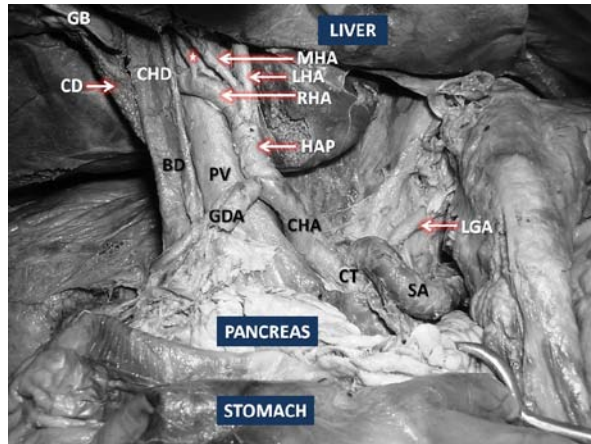
### Introduction

The hepatic artery proper is a continuation of common hepatic artery distal to the origin of gastro duodenal branch from the later. It ascends upwards within the right free margin of the lesser momentum, accompanied by bile duct and portal vein (1). At the porta hepatis, it divides into right and left branches and enters corresponding physiological lobes of the liver. The right hepatic branch gives cystic artery branch to the gall bladder before entering the liver. Within the liver it usually divides into anterior and posterior branches to supply V, VI, VII and VIII hepatic segments. The anterior branch may also supply the I segment (1). Variations affecting the origin of right hepatic arteries are quite common but its variant course is comparatively rare. In estimation, the normal hepatic arterial anatomy reported to be approximately 50–80% of cases (2). The most common anomalies of the right

hepatic artery involve a replaced or accessory right hepatic artery (3). Hepatic transarterial interventional therapies are an option of treatment for the hepatocellular carcinoma but this crucial procedure involving chemoembolization and radiation embolization require ample knowledge of anatomy of individual arterial course and branching pattern in order to select the correct technique. This not only facilitates the treatment process but also avoid vascular complications (4).

### Case Report

During routine dissection of coeliac trunk for undergraduate medical student, we observed an abnormally trifurcated hepatic artery proper into right, middle and left hepatic branches before reaching porta hepatis (Fig. 1). The middle and left hepatic branches entered the substance of liver through the porta hepatis

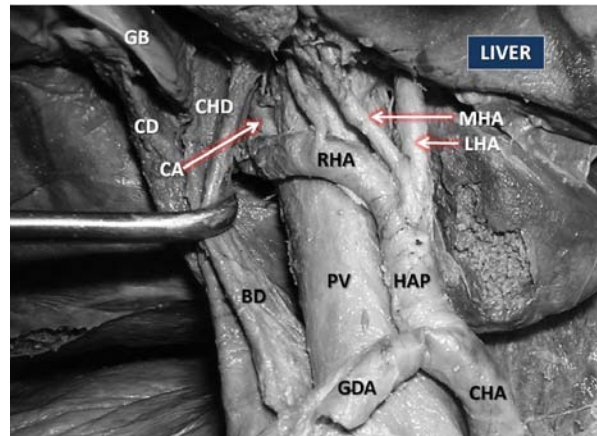


**Figure 1:** Dissection of the coeliac trunk (CT) and its branches showing the normal origin of hepatic artery proper (HAP) and gastroduodenal artery (GDA) from common hepatic artery (CHA). HAP trifurcating to give middle (MHA), Left (LHA) and Right hepatic artery (RHA). RHA on its further course turning right deep to common hepatic duct (CHD) and giving branch to liver (\*). SA- splenic artery, LGA- left gastric artery, PV- portal vein, BD- bile duct, CD- cystic duct, GB- gall bladder

as is normal, but the right hepatic artery took an unusual course towards the gall bladder fossa between portal vein posteriorly and common hepatic duct anteriorly (Fig. 2). Before it took an abnormal course towards the fossa for gall bladder, it gave a hepatic branch which entered the liver substance through porta hepatis. In its course, it also gave the cystic artery to the gall bladder deep to common hepatic duct shortly before entering the liver through the fossa. This altered arterial configuration was found in the supracolic compartment of an elderly male cadaver aged approximately 70 years. No other vascular variations in this region were noted.

## Discussion

Normally the hepatic artery proper terminates in the porta hepatis of the liver by dividing into right and left hepatic branches to supply corresponding physiological lobes of the liver. Diverged vascular pattern persists as a result of in-coordinated vasculogenesis during early embryonic period which in turn leads to variant course or termination patterns. Variations pertaining to branches of coeliac trunk particularly the hepatic arteries are of substantial importance in surgical procedures involving liver such as liver transplantations, laparoscopic surgery and also in radiological interventions (5). Prevalence of variant right hepatic arteries is estimated to be lower than that of left (6).



**Figure 2:** Closer view of variant course and branching pattern of right hepatic artery (RHA). CHA- common hepatic artery, HAP: hepatic artery proper, MHA: middle hepatic artery, LHA- left hepatic artery. CHD- common hepatic duct, PV- portal vein, BD- bile duct, CD- cystic duct, GB- gall bladder, GDA- gastroduodenal artery

In the earliest classification of the variant forms of hepatic artery by Michel's, the accessory and replaced type of hepatic artery was introduced (7). However, in subsequent classification by Hiatt it was not considered as separate entity, as these cannot be distinguished by angiography (3). The prevalence of normal hepatic arterial pattern reported to be 51 to 80% as studied by digital angiography (8, 9). While in the remaining cases, 20% of variation is attributed to left and middle hepatic arteries and 25% of incidences accounts for replaced and accessory hepatic artery. Generally, the former variation not demonstrable by sonography while the later may be imaged by sonography method (10).

The variant course of the RHA is not as common as its variant origin. Of the reported variant course, tortuous course of it forming caterpillar hump or Moynihan's hump has been reported by few authors so far (11,12). Anomalous course exhibited by common hepatic artery and right hepatic artery was reported by Badagabettu et al, (13) as an uncommon phenomenon.

Ligation of the hepatic artery without ascertaining its variant form, might lead to iatrogenic biliary injury and cause breakdown of the biliary-enteric anastomosis (14). To avoid potential complications, surgeons must have a comprehensive understanding of variant course as well as branching pattern of hepatic artery.

## Conclusion

Abnormal termination of the right hepatic artery associated with its anomalous branching pattern as we reported here is rarest of all its variations. Its knowledge is thus essential before undertaking surgical and radiological procedures in the supracolic compartment of the abdominal cavity. The variant branching and termination of hepatic arterial tree also makes important implications in interventional and therapeutic procedures like in hepatic arterial chemotherapy and hepatic arterial embolization.

## References

1. Standring S. Gray's Anatomy: The anatomical basis of clinical practice. 39<sup>th</sup> ed. Edinburgh: Elsevier Churchill Livingstone, 2005, pp-1214-5.
2. Ramanadham S, Toomay SM, Yopp AC, et al. Rare hepatic arterial anatomic variants in patients requiring pancreatoduodenectomy and review of the literature. *Case Rep Surg* 2012; ID 953195.
3. Hiatt JR, Gabbay J, Busuttill RW. Surgical anatomy of the hepatic arteries in 1000 cases. *Ann Surg* 1994; 220(1): 50–2.
4. Furuta T, Maeda E, Akai H, et al. Hepatic segments and vasculature: projecting CT anatomy onto angiograms. *Radiographics* 2009;29(7): 1-22.
5. Munshi IA, Fusco D, Tashjian D, Kirkwood JR, Polga J, Wait RB. Occlusion of an aberrant right hepatic artery, originating from the superior mesenteric artery, secondary to blunt trauma. *J Trauma* 2000; 48(2): 325-6.
6. Covey AM, Brody LA, Maluccio MA, Getrajdman GI, Brown KT. Variant hepatic arterial anatomy revisited: digital subtraction angiography performed in 600 patients. *Radiology* 2002; 224(2): 542-7.
7. Michels NA. Newer anatomy of the liver and its variant blood supply and collateral circulation. *Am J Surg* 1966; 112(3): 337-47.
8. Chen CY, Lee RC, Tseng HS, Chiang JH, Hwang JI, Teng MM. Normal and variant anatomy of the hepatic arteries: angiographic experience. *Zhonghua Yi Xue Za Zhi* 1998; 61(1): 17-23.
9. Kamel IR, Kruskal JB, Pomfret EA, Keogan MT, Warmbrand G, Raptopoulos V. Impact of multidetector CT on donor selection and surgical planning before living adult right lobe liver transplantation. *AJR Am J Roentgenol* 2001; 176(1): 193–200.
10. Ralls PW, Quinn MF, Rogers W, Halls J. Sonographic anatomy of the hepatic artery. *AJR Am J Roentgenol* 1981; 136(6): 1059-63.
11. Johnston EV, Anson BJ. Variations in the formation and vascular relationships of bile ducts. *Surg Gynecol Obstet* 1952; 94(6): 669–86.
12. Priti LM, Lakshmi R. Variant right hepatic artery forming Moynihan's hump- clinical relevance. *IJAV* 2010; 3: 144-5.
13. Badagabettu SN, Sirasanagandla SR, Kumar N, Shetty SD. Hepatosplenic trunk associated with tortuous course of right hepatic artery forming caterpillar hump. *N Am J Med Sci* 2012; 4(8): 376-8.
14. Yoshida T, Matsumoto T, Morii Y, et al. Implications of arterial anatomy in patients with cancer of the periampullary region. *Hepatogastroenterology* 2005; 52(61): 8-12.