

Case Report

A Rare Bilateral Asymmetric Variation of the Anterior Belly of Digastric Muscle

Raju S¹, Kanchana L¹, Venu MN², Raghu J², Srinivasa RS² (✉)

¹Department of Anatomy, Rajiv Gandhi Institute of Medical Sciences, Cuddapah, Andhra Pradesh, 516003, India.

²Department of Anatomy, Melaka Manipal Medical College (Manipal Campus), Manipal University, Madhav Nagar, Manipal, Karnataka State, 576104, India.

Abstract

Accessory bellies of digastric muscle may alter the movements of mandible and hyoid bone. Even they cause difficulty in the clinical diagnosis of pathological masses in the submental area and also interfere with successful surgeries in the anterior neck region. The anomalies of the anterior belly of digastric muscle (ABD) are uncommon. However, reporting of possible attachments and arrangement of muscle fibres is of tremendous clinical importance. In the present case, we report bilateral asymmetric ABD in adult male cadaver. Both accessory muscles originated from digastric fossae. Right belly inserted to the median raphe of mylohyoid muscle. Left belly had two segments: upper anterior segment inserted to the median raphe whereas the lower posterior segment inserted to the median raphe and ipsilateral intermediate tendon. Accessory bellies of anterior belly reported here is unique in their arrangement and documentation of such observation may add further information to existing literature.

Keywords: Anterior belly, accessory belly, digastric muscle, mylohyoid, median raphe

Correspondence:

Srinivasa Rao Sirasanagandla, Department of Anatomy, Melaka Manipal Medical College (Manipal Campus), Manipal University, Madhav Nagar, Manipal, Karnataka State, 576104, India. Tel: 91 7897456466 Fax: +91-820-2571905 Email: seenaih.anat@gmail.com

Date of submission: 10 Apr, 2014

Date of acceptance: 27 Sept, 2014

Introduction

Digastric muscle belongs to the suprahyoid muscle group. It has anterior and posterior bellies, an intermediate tendon that joins them. Posterior belly originates from temporal bone mastoid notch and traverses a course downwards along the stylohyoid muscle, and then it ends by continuing with the intermediate tendon. Intermediate tendon continues with anterior belly which finally attaches to the digastric fossa of the mandible, below the genial tubercles. Both bellies differ in their embryonic development. Anterior belly derived from the mesoderm of first branchial arch, whereas mesoderm of second pharyngeal arch form posterior belly. The muscle causes depression of mandible and also the elevation of hyoid bone, and thus helps in mastication

and deglutition (1). Digastric muscle frequently shows variations, and majority of the possible variations of this muscle are well described in the literature (2). Digastric muscle shows variation in its anterior belly, posterior belly and intermediate tendon (2). There is a possibility of isolated variation of anterior belly or posterior belly digastric muscle, as both muscle shares different sources of development. In the present case, we report a case of bilateral asymmetric ABD and discuss its medical and surgical significance.

Case Report

While dissecting the anterior triangle, in a male cadaver aged about 55 years, we observed a bilateral asymmetric ABD. During routine dissection of anterior triangle of the neck, the skin, superficial fascia

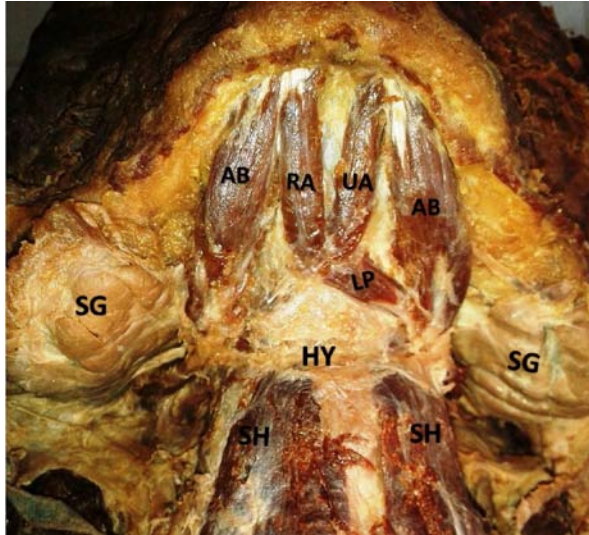


Figure 1: Dissection of anterior neck region showing the accessory belly of anterior belly of digastric muscle on each side. (RA: right accessory belly; UA: upper anterior segment of left accessory belly; LP: lower posterior segment of left accessory belly; SG: submandibular gland; HY: hyoid bone; SH: sternohyoid muscle)

and deep fascia of neck were removed. On either sides, digastric muscle was exposed and it consisted of anterior and posterior bellies. Posterior belly originated from temporal bone mastoid notch and ended as intermediate tendon. Then, the intermediate tendon continued with the anterior belly which was inserted to the lateral half of the digastric fossa of the mandible. In addition, there were two accessory anterior bellies on each side of the midline. On the right, accessory belly originated from medial portion of the digastric fossa and inserted to the median raphe and mylohyoid muscle. On other hand, left accessory belly had two segments: upper anterior segment and lower posterior segment. Upper anterior segment originated from the medial portion of the left digastric fossa and inserted to the median raphe and mylohyoid muscle. The lower segment was inserted medially to the mylohyoid raphe and laterally to the margin of the ipsilateral intermediate tendon. These accessory bellies divided the submental triangle into different compartments (Fig. 1).

Discussion

In the present case, we observed bilateral variation of ABD. Variations of ABD are not uncommon. Rarely, anterior belly may be absent completely (3). In a cadaveric study by De-Ary-Pires et al. (2) the variations of anterior belly were described into 5 types. In typ1-4, anterior belly consist of one, two, three and four bellies associated with extra slips, respectively.

Further, mentohyoid muscle described as type 5. In their study accessory bellies were found in 18% of cases (2). Fujimura et al. (4) observed the unusual anterior bellies in 24.1% of cases. Celik et al. (5) described quadrification of ABD. Sarikcioglu et al. reported a case of triplication of anterior belly (6). Anterior belly variations can occur unilaterally (7) or bilaterally (8,9,10). Sometimes, they can occur in the midline (11). Earlier, authors have been described that unilateral variations are more common than bilateral variation (7,8). However, Liquidato et al. (10) have questioned such observation. Noting of unilateral or bilateral variation is of considerable clinical perspective. Unilateral variation alters the symmetry of the suprahyoid muscles and it may results in functional disturbances of movements of mandible and hyoid bone. However, such disturbances depend on the attachments, direction of fibers and innervation of the variant bellies (12). Asymmetry may also lead to confusion during the clinical diagnosis of anterior neck region while performing imaging techniques. Unusual bellies are confused with abnormal masses of lymph nodes and/or tumors. Earlier authors reported the bilateral anomalies of ABD anterior belly of digastric muscle (8,9,10,13). Mascaro et al. (13) identified an accessory belly on each side had two segments. These two segments are connected each other in the midline by the connective tissue. Bilateral variation reported in this case is different from the previous reports. Accessory belly on the left side had two segments and there was no segmentation in the right belly. Right belly and the two segments of the left belly were found to converge and insert to the median raphe as well as surrounding portion of the mylohyoid muscle. Though accessory bellies observed bilaterally, arrangement and amount of muscle mass was different on both sides, and thus resulted in the asymmetry of the digastric muscle.

Occurrence of supernumerary muscles could be due to the abnormal development of the muscle primordium. The first branchial arch gives rise to ABD. Any abnormalities of the neural crest cells from the first pharyngeal arch will results in the additional or accessory bellies of anterior belly (14). Knowledge of anatomic variants of the anterior belly is clinically important during surgeries involving the anterior neck region. Possible arrangement of the accessory bellies and their attachment to the surrounding bones or muscles could help the physicians during the interpretation of pathologic masses in the submental area. ABD is frequently used in plastic surgeries for the functional restoration of the lower lip in cases of facial nerve palsy (15). Prior knowledge of possible anomalies is also important to avoid confusion while raising the myocutaneous flaps on ABD.

References

1. Williams PL, Warwick R, Dyson M, Bannister LH. Gray's anatomy. 37th ed. London: Churchill Livingstone, 1989, pp 584-5.
2. De-ary-pires B, Ary pires R, Pires neto MA. The human digastric muscle: patterns and variations with clinical and surgical correlations. *Ann Anat* 2003; 185(5): 471-9.
3. Ozgursoy OB, Kucuk B. Unique variation of digastric muscle: a confusing landmark for head and neck surgeons. *Acta Otolaryngol* 2006; 126(8): 881-3.
4. Fujimura A, Onodera M, Feng XY, et al. Abnormal anterior belly of the digastric muscle: a proposal for the classification of abnormalities. *Anat Sci Int* 2003; 78(3): 185-8.
5. Celik HH, Aldur MM, Ozdemir B, Aksit MD. Abnormal digastric muscle with unilateral quadrification of the anterior belly. *Clin Anat* 2002; 15(1): 32-4.
6. Sarikcioglu L, Demir S, Oguz N, Sindel M. An anomalous digastric muscle with three accessory bellies and one fibrous band. *Surg Radiol Anat* 1998; 20(6): 453-4.
7. Sargon MF, Celik HH. An abnormal digastric muscle with three bellies. *Surg Radiol Anat* 1994; 16(2): 215-6.
8. Peker T, Turgut HB, Anil A. Bilateral anomaly of anterior bellies of digastric muscles. *Surg Radiol Anat* 2000; 22(2): 119-21.
9. Turan-ozdemir S, Oygucu IH, Kafa IM. Bilateral abnormal anterior bellies of digastric muscles. *Anat Sci Int* 2004; 79(2): 95-7.
10. Liquidato BM, Barros MD, Alves AL, Pereira CSB. Anatomical study of the digastric muscle: variations in the anterior belly. *Int J Morphol* 2007; 25(4): 797-800.
11. Guelfguat M, Nurbhai N, Solounias N. Median accessory digastric muscle: radiological and surgical correlation. *Clin Anat* 2001; 14(1): 42-6.
12. Stockstill JW, Harn SD, Underhill TE. Clinical implications of anomalous muscle insertion relative to jaw movement and mandibular dysfunction: the anterior belly of the digastric muscle in a cadaver. *J Craniomandib Disord* 1991; 5(1): 64-70.
13. Mascaro MB, Picoli LC, Santos FM, Bonsi AB, Souza MR, Prosdocimi FC. Anatomical variation of the anterior belly of the digastric muscle: case report and clinical implications. *J Morphol Sci* 2011; 28(1): 72-5.
14. Loukas M, Louis RG, Kapos T, Kwiatkowska M. A case of a bilateral accessory digastric muscle. *Folia Morphol (Warsz)* 2005; 64(3): 233-6.
15. Tan ST. Anterior belly of digastric muscle transfer: a useful technique in head and neck surgery. *Head Neck* 2002; 24(10): 947-54.