

Case Report

Congenital Urethrocutaneous Fistula: An Interesting Case

Roger AI¹, Anne Rachel J² (✉)

¹Department of Surgery, ²Department of Paediatric Surgery, Sarawak General Hospital, Jalan Hospital 93586, Kuching, Sarawak, Malaysia.

Abstract

A congenital urethrocutaneous fistula is a rare anomaly which was first described in 1962 by Gupta. Clinically, children present when their guardian is alarmed by either frequent urinary dribbling or unusual stream when they pass urine. This congenital anomaly can present in isolation or be accompanied by a chordee, hypospadias and anorectal malformations in a newborn. The surgical management will either be a primary repair of the fistula or converting it to a hypospadias before proceeding with a single or staged hypospadias repair. Surgical technique will depend on the local tissue factors and associated anomalies.

Keywords: Urethrocutaneous fistula, hypospadias, urethra, anomalies, surgery

Correspondence:

Anne Rachel John, Department of Paediatric Surgery, Sarawak General Hospital, Jalan Hospital 93586, Kuching, Sarawak, Malaysia. Tel: +0060198899756 Fax: +006082242751 Email: msannejohn@yahoo.com

Date of submission: 12 May, 2014

Date of acceptance: 5 Nov, 2014

Introduction

Congenital urethrocutaneous fistula and chordee without hypospadias were first described in 1962 by Gupta (1) and since then further case reports have been published within the literatures over the years concerning this rare anomaly and its variations. Local or segmental deficiency of the urethral plate has been identified as crucial in the development of this anomaly although alternative hypotheses have been proposed by other authors. Here, we review the pathology behind the development of congenital urethrocutaneous fistula and briefly discuss the available surgical options.

Case Report

A 7-year-old boy was noticed by his mother to have persistent dribbling while passing urine for over a year before coming to our attention at the clinic. He was uncircumcised and did not have any predisposing trauma prior to this. On further examination of his genitalia, he was noted to have a meatal opening at the subcoronal region with an accompanying chordee. In

addition, the distance between the fistula and the meatal opening is short.

An appropriate sized feeding tube was first gently introduced into the fistulous opening via the external urinary meatus. A degloving incision was then made, and the fistula tract was carefully delineated. Intraoperatively, the spongiosus tissue around the fistulous tract was found to be lacking in contrast to the distal urethra which was covered by normal spongiosus. The tract was excised, and a two layered repair of the resulting defect was performed. Prior to the end of the surgery, a 14 Fr catheter was inserted and kept in place for ten days after the surgery to preserve the anastomotic patency. Post operatively, his recovery was uneventful and he was able to pass urine after the removal with no leak noted. He was discharged well with a follow up clinic appointment.

Discussion

Congenital urethrocutaneous fistula can present in isolation or combination with a hypospadias or chordee.

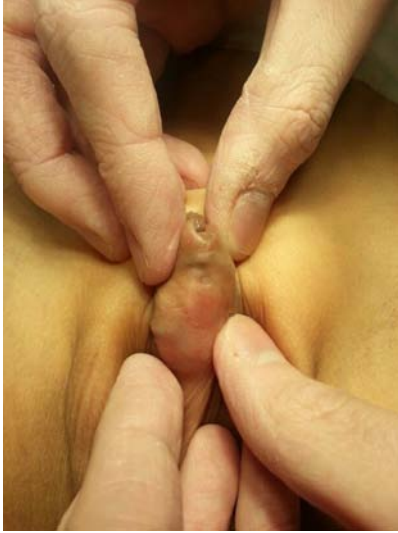

Figure 1: Fistula opening on the ventral aspect of the penis

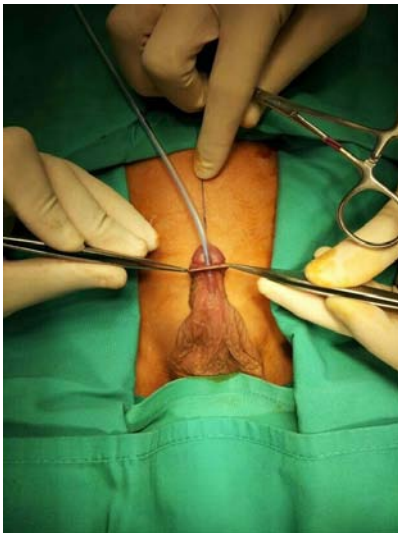


Figure 2: Intraoperative view. Fistula is delineated prior to repair

It has also been reported to have association with anorectal malformations (2,3,4,5).

The pathology that leads to the development of a congenital urethrocutaneous fistula remains unclear. This is probably due to varying accompanying anomalies that present in tandem with this condition. To start with, Goldstein hypothesized that the arrest of the urethral groove closure could have been implicated by a momentary disruption of the effect of testosterone to the specific tissues (6). While Oulbourne hypothesized that a specific handicap in the urethral plate resulted in the distal migration of the urethral plate to stop with a resultant deficiency in a portion of the plate (7). Alternatively, a misalignment between

the glanular and penile urethra as well as pressure atrophy from penile necrosis from the heels of the baby's foot have also been coined in the development of this particular anomaly (8).

In general, the repair of a congenital anterior urethrocutaneous fistula relies upon the configuration of the fistula, local tissue factors and also other accompanying anomalies which can be present. In cases of isolated fistula with intact spongiosum, various techniques have been described which includes a modified Dennis-Browne urethroplasty, pedicle flap, preputial bound skin flap or even direct closure (9). In contrast, if they are associated hypospadias, chordee, local tissue deficiency or stenosis of the external meatus, then converting the anomaly to a hypospadias with either a single or staged repair will be the preferred approach. At present, evidence still remains sparse as to which operative strategy provides the best surgical outcome in these patients.

References

1. Gupta SC. An unusual type of hypospadias. *Br J Plast Surg* 1962; 15: 191-3.
2. Caldamone AA, Chen SC, Elder JS, Ritchey ML, Diamond DA, Koyle MA. Congenital anterior urethrocutaneous fistula. *J Urol* 1999; 162(4): 1430-2.
3. Olbourne NA. Congenital urethral fistula: Case reports. *Plast Reconstr Surg* 1976; 57(2): 237-9.
4. Welch KJ. Hypospadias In: Ravitch MM, Benson CD, Aberdeen E, Randolph JG, editors. *Pediatric Surgery*. 3rd Ed. Chicago: Year Book Medical Publishers, 1979, pp 1353-76.
5. Elder JS. Abnormalities of the genitalia in boys and their surgical management. In: Wein AJ, Kavoussi LR, Novick AC, Partin AW, Peters CA, editors. *Campbell-Walsh Urology*. 9th Ed. Philadelphia, Pa, USA: Saunders, 2007, pp 3745-60.
6. Goldstein M. Congenital urethral fistula with chordee. *J Urol* 1975; 113(1): 138-40.
7. Nakane A, Hayashi Y, Kojima Y, et al. Congenital urethrocutaneous fistula. *Int J Urol* 2000; 7(9): 343-4.
8. Cook WA, Stephens FS. *Urologic Surgery in Neonates and Young infants*. Philadelphia: WB Saunders, 1990, pp- 724-25.

9. Spinelli C, Pucci V, Menchini C, et al. A congenital urethrocutaneous fistula in a boy whose mother was exposed to ionizing radiations: case report and literature review. *Case Rep Urol* 2013; 2013: 525386.