

**Original Research Article****Varicocele Surgery Improves Sperm Count in Infertile Oligospermic Patients and so Improves Fertility; A Study in a Tertiary Care Hospital**

Jamaluddin M, Abbas Hussain SM, Ayesha AK, Hina RS

Department of Surgery, Unit-I, Karachi Medical and Dental College &amp; Abbasi Shaheed Hospital, Nazimabad, Karachi, Pakistan.

**Abstract**

The objective of this study was to find out the role of varicocele surgery in oligospermic infertile patients. It was a prospective and descriptive study carried out in Surgical Unit-I, Abbasi Shaheed Hospital and Karachi Medical and Dental College (KMDC), Karachi from April 2004 to March 2014. In this study, all patients of infertility due to low sperm count having bilateral varicocele were included while those patients having azoospermia or patients with unilateral varicocele were excluded. All patients were clinically assessed for bilateral varicocele and confirmed by ultrasonography of scrotum and relevant investigations were done. Patients were prepared for varicocele surgery and ligation of pampiniform plexus done. Semen analysis were done during follow up and results were analyzed on SPSS version 14. Total fifty seven patients (n=57) were included in which age range was 20 to 30 years in 33.3%, 31 to 40 years in 42.1%, 41 to 50 years in 19.3% and 51 years or onwards in 05.3% patients only. Chronic smoking was found in 68.4% patients while 31.6% were nonsmokers. Normal testes were found in 77.19% while 22.81% had smaller (atrophied) testes. Very low sperm count was in 15.79%, 50.88% had low sperm count and 33.33% had near normal sperm count. All patients were operated for bilateral varicocele and discharged. Follow-up semen analysis showed improvement and semen analysis became normal in 19.3% after six months, 21.05% after nine months and 36.84% after one year of surgery while 22.81% had no improvement even after one year of surgery. Thus, patients with bilateral varicocele having low sperm count showed improvement in sperm count after varicocele surgery and so infertile patients may become fertile after varicocele surgery.

**Keywords:** Varicocele, oligospermia, azoospermia, pampiniform plexus, semen analysis.**Correspondence:**

Muhammad Jamaluddin, Department of Surgery, Unit-I, Karachi Medical and Dental College &amp; Abbasi Shaheed Hospital, Nazimabad, Karachi, Pakistan. Tel: 00923002167612 Email: drmjdin@hotmail.com

Date of submission: 27 Feb, 2015

Date of acceptance: 12 Jul, 2015

**Introduction**

Varicocele is the abnormal dilation of the pampiniform plexus of veins of spermatic chord (1) and it is present in 15% to 20% of the general population, but approximately 35% to 40% of male patients are presenting for an evaluation of their infertility (2). Varicocele can cause testicular damage and infertility but there is no evidence which indicates a varicocele treatment in infertile men who have normal semen analysis or in men with subclinical varicocele. Varicocele surgery may be effective in infertile patients with subnormal semen analysis or unexplained

infertility. As it is present in 15-20% of normal males and in 40% of males with infertility so this disorder is a challenge for the physicians involved in the diagnosis and treatment. Varicocele may cause progressive testicular lesions and if untreated it can lead to testicular atrophy and therefore it can cause male infertility (3). The mechanisms involved in varicocele formation are not well known and are probably multiple, differing from one patient to another (4) but valve dysfunction, ontogenetic collateral formation and the nutcracker phenomenon seem to act synergistically. Elevated hydrostatic pressure, hyperthermia and antisperm agents are thought as possible causes for the pathophysiology

how varicocele induce infertility. However, the combination of patient's lifestyle, genetic factors and the consequences of reflux into the pampiniform plexus are also believed to contribute to the infertility. Although venography stays the gold standard, the combination of physical examination, color Doppler ultrasound (5) and thermography has the highest sensitivity and specificity to diagnose a varicocele (6) but color Doppler's ultrasound is the method of choice (7). Recent studies showed that azoospermia is observed in 10-15% of infertile men and 60% of these cases are classified as having non-obstructive azoospermia. Non-obstructive azoospermia results from testicular failure, which may be one of the causes of the presence of varicocele. Varicocele is found in 5-10% of men with non-obstructive azoospermia and its surgery is associated with the appearance of spermatozoa in the ejaculate in 21-55% of cases (8). Therefore, the main aim of the present study was to assess the improvement of sperm count after varicocele surgery in oligospermic infertile males who have bilateral varicocele.

### Materials and Methods

This study was a prospective and descriptive study, conducted in surgical unit-I, Abbasi Shaheed Hospital, Karachi Medical & Dental College, Karachi from April 2004 to March 2014. All male infertile patients with the diagnosis of bilateral varicocele who presented in surgical outpatient department during this period were included in this study. History was taken especially about smoking and over work. These patients were then assessed clinically, especially both testes and epididymis and for presence of bag of worm like feeling in the scrotum bilaterally and confirmed by Doppler's ultrasound of scrotum. Routine lab tests including complete blood count, random blood sugar, urine detail report, Doppler's ultrasound of scrotum and semen analysis were done. Patients with tuberculosis, renal diseases, unilateral varicocele, undescended testes, epididymo-orchitis or inguinal hernia were excluded from the study. All patients were admitted and prepared for bilateral varicocele surgery under spinal anesthesia on elective list. They were informed about the study and written consent was taken. Bilateral inguinal approach was used for varicocelectomy. Patients were discharged on the next day according to hospital protocol. All patients were followed up regularly and their semen analysis were done after six months, nine months and one year postoperatively and recorded. Results were analyzed on spss version 14.

### Results

All fifty seven male patients (n=57) were married, infertile and had bilateral varicocele. The age range was

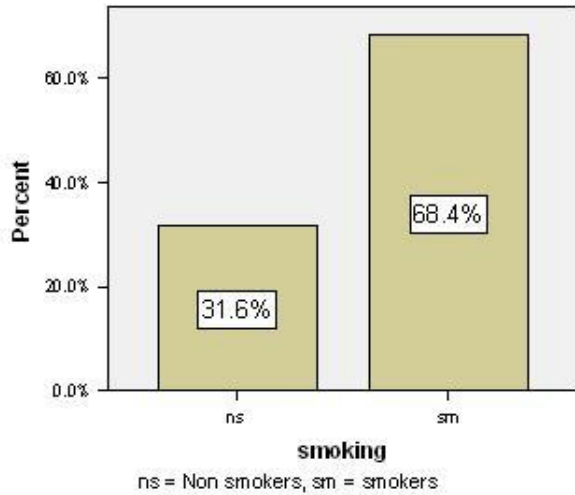
**Table 1:** Age range of the patients.

Age range (years)	Number of patients (n=57)	Percentage (%)
20 to 30	19	33.3
31 to 40	24	42.1
41 to 50	11	19.3
> 50	03	05.3
Total	57	100.0

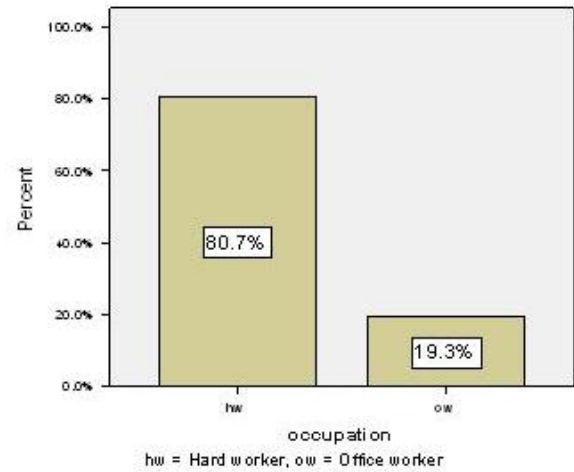
20 to 30 years in 19 patients (33.3%), 31 to 40 years in 24 patients (42.1%), 41 to 50 years in 11 patients (19.3%) and 51 years to onwards in 03 patients (05.3%) as shown in Table 1. Chronic smoking was found in 39 patients (68.4%) while 18 patients were non-smokers (31.6%) (Fig. 1). Heavy work and exertion was noted in 46 patients (80.7%) and 11 patients (19.3%) were office worker (Fig. 2). Patients with normal testes were 44 patients (77.19%) while 13 patients (22.81%) had smaller testes out of them 07 patients (12.28%) had bilateral smaller testes and 06 patients (10.53%) had smaller unilateral (atrophied) testes (Fig. 3). Very low sperm count was found in 09 patients (15.79%) (< 5million/ml), 29 patients (50.8%) had low sperm count (5-10million/ml) and 19 patients (33.33%) had near normal sperm count (10-20million/ml) (Fig. 4). All patients were operated for bilateral varicocele and discharged. Follow-up semen analysis showed improvement and their semen analysis became normal in 11 patients (19.3%) after six months of surgery, 12 patients (21.05%) after nine months of surgery and 21 patients (36.84%) after one year of surgery while 13 patients (22.81%) had no improvement (azoospermic) even after one year of surgery (Fig. 5 & Fig. 6).

### Discussion

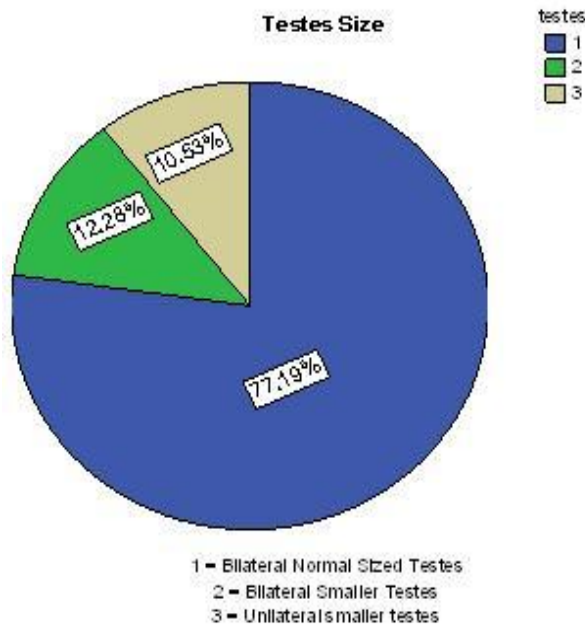
The role of varicocele surgery in infertile patients was previously considered questionable but during last few years several studies have changed this concept and now it is considered that varicocele surgery can improve the sperm count and quality in infertile patients (9). Also, during the treatment of infertility in males in few studies, it was found that varicocele was a common association (10). Therefore, the main features of infertile patients having bilateral varicocele were discussed in this study including patient's age, smoking habit, profession, testicular size, diagnostic modality like Doppler's ultrasound, preo-perative sperm count and postoperative sperm count after six months, nine months and one year. In our study, most of the patients were in between 30 to 40 years and only few were above 50 years of age which was similar to a study done in Shiraz by Mahboubi et al. (11) in which the infertile patients mean age were 36.3 years. Another study showed the mean age to be  $46 \pm 22$  years (12) but some



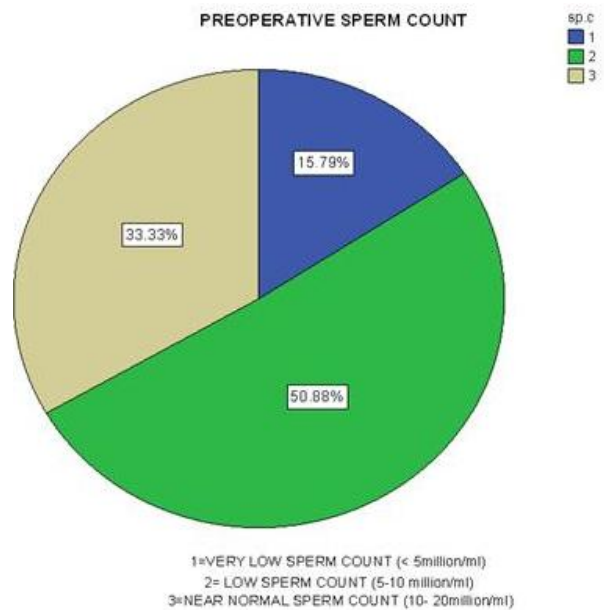
**Figure 1:** Varicocele and smoking (smokers and non-smokers).



**Figure 3:** Occupation and varicocele (hard workers and office workers).



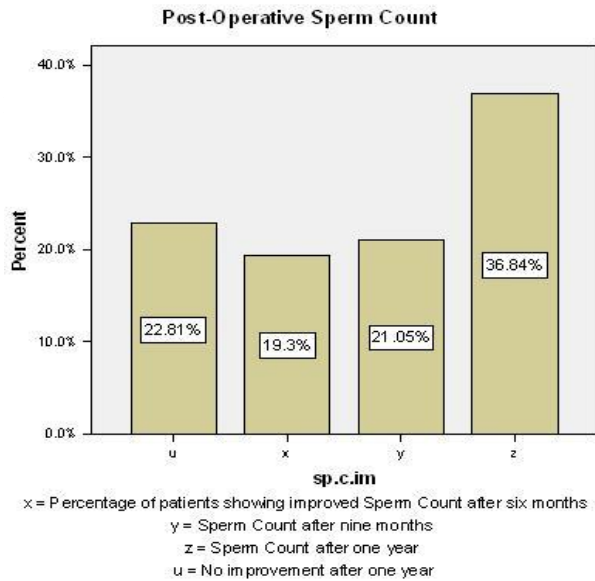
**Figure 2:** Testicular size and varicocele (normal and atrophied testes).



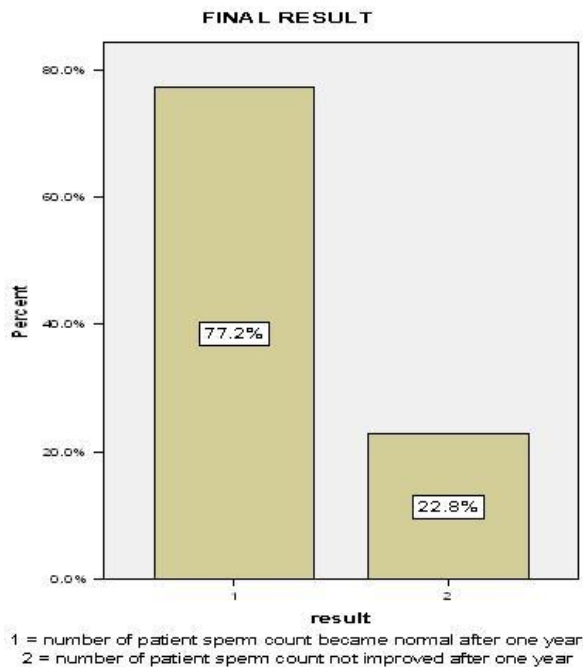
**Figure 4:** Pre-operative sperm count in varicocele patients.

studies suggested that varicocele surgery should also be done in older infertile patients as well (13). Majority of the patients in our study had normal sized bilateral testes (77.19%) and only 22.81% had smaller or atrophied testes morphologically while a study done by Pastuszak et al. (14) in Houston, USA showed that 96% of patients having testicular hypotrophy due to varicocele and also a study done in Ankara, Turkey, showed that varicocele can cause hypotrophy of the testes and so causes infertility (11). Smoking was found

in 68.4% of our patients and smoking is a risk factor for infertility or decrease sperm count according to some studies and also associated with higher percentage of varicocele compared to non-smokers (10,15). Approximately, 80% of patients in this study were hard workers by profession which was a predisposing factor for varicocele and infertility according to some studies (11). About 50% of patients in this study had low sperm count less than five million/ml pre-operatively which



**Figure 5:** Post-operative sperm count after six months of surgery.



**Figure 6:** Sperm count after one year of surgery.

was similar to a study done by Kwon and Lee (16) in Korea while few studies showed different results (17,18,19). Only 33.33% patients had near normal sperm count i.e. 10 million/ml to less than 20 million/ml but no patient had normal sperm count pre-operatively in our study but a study done in New York, USA by

Sheehan et al. (20) showed that most patients with varicocele have normal spermatogenesis and so not all patients of varicocele have infertility pre-operatively. Sperm count increased after six months of surgery which became maximum after one year post-operatively in our study which was similar to a study done in Milan, Italy by Grasso M. who showed increase in sperm count and pregnancy after 13.5 months (21,22). Only 22.81% of patients in this study had no improvement in sperm count even after one year of surgery and according to a study done in Iran, varicocele surgery may cause infertility in some patients (23) while according to other study correction of varicocele may not able to restore fertility (24).

**Conclusion**

Patients with bilateral varicocele having low sperm count showed improvement in sperm count after varicocele surgery on both sides. So infertile patients having bilateral varicocele may become fertile after its surgery.

**References**

1. Naderi G, Mohseni Rad H, Tabassomi F, Latif A. Seminal insulin-like growth factor-I may be involved in the pathophysiology of infertility among patients with clinical varicocele. *Hum Fertil (Camb)* 2015; 18(2): 92-5.
2. Capece M, Imbimbo C. The varicocele: the proper therapy for the proper patient. *Urologia* 2014; 81(3): 165-8.
3. Kovac JR, Fantus J, Lipshultz LI, Fischer MA, Klinghoffer Z. Cost-effectiveness analysis reveals microsurgical varicocele repair is superior to percutaneous embolization in the treatment of male infertility. *Can Urol Assoc J* 2014; 8(9-10): E619-25.
4. Nistal M, Paniagua R, Gonzalez-Peramato P, Reyes-Múgica M. Adolescent varicocele. *Pediatr Dev Pathol* 2014.
5. Ener K, Uçgöl YE, Okulu E, et al. Comparison of arterial blood supply to the testicles in the preoperative and early postoperative period in patients undergoing subinguinal varicocelectomy. *Scand J Urol* 2015; 49(2): 169-73.
6. Vanlangenhove P, Dhondt E, Everaert K, Defreyne L. Pathophysiology, diagnosis and treatment of varicoceles: a review. *Minerva Urol Nefrol* 2014; 66(4): 257-82.

7. Valentino M, Bertolotto M, Derchi L, Pavlica P. Children and adults varicocele: diagnostic issues and therapeutical strategies. *J Ultrasound* 2014; 17(3): 185-93.
8. Elzanaty S. Varicocele repair in non-obstructive azoospermic men: diagnostic value of testicular biopsy-a meta-analysis. *Scand J Urol* 2014; 48(6): 494-8.
9. Cho KS, Seo JT. Effect of varicocelectomy on male infertility. *Korean J Urol* 2014; 55(11): 703-9.
10. Shafi H, Esmaeilzadeh S, Delavar MA, Haydari FH, Mahdinejad N, Abedi S. Prevalence of Varicocele among Primary and Secondary Infertile Men: Association with Occupation, Smoking and Drinking Alcohol. *N Am J Med Sci* 2014; 6(10): 532-5.
11. Mahboubi M, Foroughi F, Ghahramani F, Shahandeh H, Moradi S, Shirzadian T. A case-control study of the factors affecting male infertility. *Turk J Med Sci* 2014; 44(5): 862-5.
12. Mazzola CR, Katz DJ, Loghmanieh N, Nelson CJ, Mulhall JP. Predicting biochemical response to clomiphene citrate in men with hypogonadism. *J Sex Med* 2014; 11(9): 2302-7.
13. Ollandini G, Trombetta C, Mazzon G, et al. Should older patients be offered varicocele correction to improve their fertility? *Andrology* 2014; 2(3): 402-7.
14. Pastuszak AW, Kumar V, Shah A, Roth DR. Diagnostic and management approaches to pediatric and adolescent varicocele: a survey of pediatric urologists. *Urology* 2014; 84(2): 450-5.
15. Nieschlag E. Male infertility: recent developments. *Bundesgesundheitsblatt Gesundheitsforschung Gesundheitsschutz* 2013; 56(12): 1619-27.
16. Kwon CS, Lee JH. Is semen analysis necessary for varicocele patients in their early 20s? *World J Mens Health* 2014; 32(1): 50-5.
17. Milone M, Musella M, Fernandez ME, et al. Varicocele repair in severe oligozoospermia: A case report of post-operative azoospermia. *World J Clin Cases* 2014; 2(4): 94-6.
18. Kadioglu TC, Aliyev E, Celtik M. Microscopic varicocelectomy significantly decreases the sperm DNA fragmentation index in patients with infertility. *Biomed Res Int* 2014; 2014.
19. Enatsu N, Yamaguchi K, Chiba K, Miyake H, Fujisawa M. Clinical outcome of microsurgical varicocelectomy in infertile men with severe oligozoospermia. *Urology* 2014; 83(5): 1071-4.
20. Sheehan MM, Ramasamy R, Lamb DJ. Molecular mechanisms involved in varicocele-associated infertility. *J Assist Reprod Genet* 2014; 31(5): 521-6.
21. Grasso M, Lania C, Blanco S, Confalonieri S, Grasso AA. Efficacy of spermatic vein ligation in patients affected by high grade left varicocele. *Int Braz J Urol* 2014; 40(1): 62-6.
22. Lehtihet M, Arver S, Kalin B, Kvist U, Pousette A. Left-sided grade 3 varicocele may affect the biological function of the epididymis. *Scand J Urol* 2014; 48(3): 284-9.
23. Ahmadi MR, Yasemi M, Peyman H, et al. Associated factors with male infertility: a case control study. *J Clin Diagn Res* 2014; 8(9): FC11-3.
24. Palermo GD, Kocent J, Monahan D, Neri QV, Rosenwaks Z. Treatment of male infertility. *Methods Mol Biol* 2014; 1154: 385-405.