

Case Report

Occurrence of Three Headed Sternocleidomastoid Muscle and a Common Thyro-Linguo-Facial Vein – A Case Report

Gayathri S Prabhu, Satheesha B Nayak (✉), Prakashchandra Shetty, Deepthinath Reghunathan, Prasad AM.

Department of Anatomy, Melaka Manipal Medical College (Manipal Campus), Manipal University, Madhav Nagar, Manipal, 576104 Karnataka State, India.

Abstract

Variant anatomy of muscles and veins of the neck is of importance to plastic surgeons, radiologists and general surgeons. We report the variations of sternocleidomastoid muscle and veins of the neck in the present article. Right sternocleidomastoid muscle had three heads of origin. The third head took its origin from the clavicle just lateral to the usual clavicular head. All the three heads were about 4 inches long and united with each other at the level of thyroid cartilage. There was no external jugular vein on the right side. The retromandibular vein united with facial vein to form common facial vein. Common facial vein joined with superior thyroid and lingual veins to form a thyro-linguo-facial trunk one inch below the angle of mandible. This trunk was about 2 inches long and terminated into the internal jugular vein. Knowledge of this case could be useful while raising a sternocleidomastoid flap, administering anesthesia to brachial plexus, neck surgeries and carotid endarterectomy.

Keywords: Sternocleidomastoid muscle, jugular veins, neck muscles, submandibular gland

Correspondence:

Satheesha Nayak B, Department of Anatomy, Melaka Manipal Medical College (Manipal Campus), Manipal University, Madhav Nagar, Manipal, 576104 Karnataka State, India. Tel: +91 8202922519/+91 9844009059 Fax: +91 8202571905. Email: nayaksathish@gmail.com

Date of submission: 26 Feb, 2015

Date of acceptance: 20 Aug, 2015

Introduction

Sternocleidomastoid muscle is an important muscle of the neck. Apart from flexing the head, it acts as an accessory muscle of respiration. It protects the contents of the carotid sheath from direct injuries. It usually has two heads of origin; the sternal and clavicular head. The two heads unite with each other in the lower part of the neck. Sternocleidomastoid is inserted to the mastoid process. Many of its variations have been reported. Some of its reported variations include its fusion with trapezius muscle; separate sternomastoid and cleidomastoid parts; absence of insertion to the mastoid process; a bifurcated insertion; absence of sternal head and absence of clavicular head (1). External jugular vein is normally formed by meeting of posterior division of retromandibular vein and the posterior auricular vein. It terminates into the subclavian vein.

External jugular veins are highly variable. One or both of them may be absent, too small or too large, may cross the clavicle, may be doubled, or may receive veins like cephalic, facial or lingual. The common facial vein is normally formed by meeting of facial vein and anterior division of the retromandibular vein. It may terminate into the anterior jugular vein or external jugular vein. It may receive lingual, pharyngeal or submental veins. We observed a relatively rare type of venous trunk formed by the union of common facial, lingual and superior thyroid veins. We discuss the clinical importance of this trunk.

Case Report

During our routine dissection classes for first year medical students, we observed concurrent variations of the sternocleidomastoid muscle and veins of the neck.

The sternocleidomastoid muscle had three heads. The usual sternal and clavicular heads had normal origin as described in the anatomy text books. The unusual third head took its origin from the superior surface of the shaft of the clavicle immediately lateral to the origin of the usual clavicular head. The third head was as bulky as the usual clavicular head. All the three heads were about 4 inches long and united with each other at the level of thyroid cartilage (Fig. 1). The nerve supply of the muscle was derived from the spinal accessory nerve. The insertion of the muscle was to the mastoid process. The retromandibular vein remained as a single vein without division into two divisions.

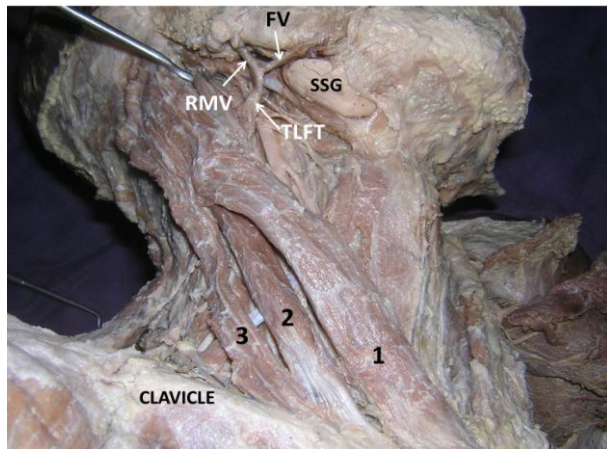


Figure 1: Dissection of the right side of neck showing three headed sternocleidomastoid muscle. (1,2,3 – three heads of sternocleidomastoid muscle; FV – facial vein; RMV – retromandibular vein; TLFT – thyro-linguo-facial trunk; SSG – submandibular salivary gland).

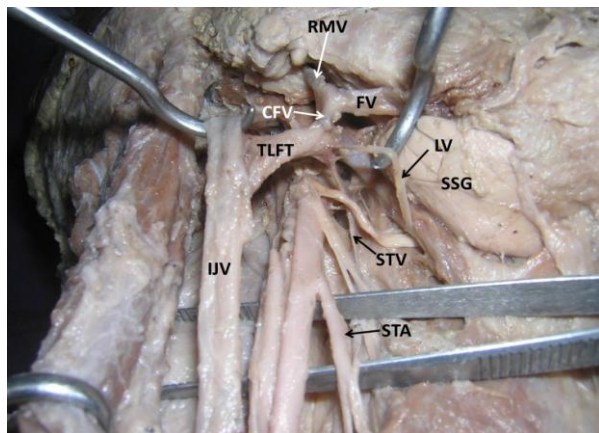


Figure 2: Dissection of the right side of neck showing the formation and termination of common thyro-linguo-facial trunk. (FV – facial vein; RMV – retromandibular vein; CFV – common facial vein; TLFT – thyro-linguo-facial trunk; SSG – submandibular salivary gland; LV – lingual vein; STV – superior thyroid vein; IJV – internal jugular vein; STA – superior thyroid artery).

Entire retromandibular vein joined with facial vein to common facial vein. The external jugular vein was totally absent. The lingual and superior thyroid veins joined the common facial vein to form a common thyro-linguo-facial trunk one inch below the angle of mandible. This trunk was about 2 inches long and terminated by opening into the internal jugular vein (Fig. 2). All these variations were found on the right side of the neck of an adult male cadaver aged approximately 70 years.

Discussion

A thorough knowledge of variant attachments of the sternocleidomastoid muscle is of utmost importance to neck surgeons. Sternocleidomastoid muscle often shows variations in its attachments. In a study conducted by Saha et al., the muscle showed variations in 27.8% of individuals (2). Presence of three heads (3) and four heads of origin (4,5) of this muscle were reported. Congenital absence of the sternocleidomastoid is a rare variation. One such absence has been reported recently (6). Sternocleidomastoid and trapezius muscles develop from the last two occipital and upper cervical myotomes. At 9mm stage of the embryo, the muscle mass splits to form two separate muscles. Additional splitting of the muscle could be the possible reason for having additional heads. Additional heads of sternocleidomastoid are indeed a boon for plastic surgeons because sternocleidomastoid flaps are widely used to prevent leakage after oesophageal reconstruction (7), to prevent fistula formation after total laryngectomy (8), to prevent Fray's syndrome after superficial parotidectomy (9) and in oral and maxillo-facial surgeries (10). Knowledge of variations, especially presence of additional clavicular heads is essential since they may make the central venous catheterization and brachial plexus anesthesia difficult. Though the presence of a third head of sternocleidomastoid is a common finding, the current case is unique due to the level of union of three heads. The three heads in current case united to form a single belly at the level of thyroid cartilage.

External jugular vein is one of the most commonly variable veins of the neck. It may be absent unilaterally or bilaterally or even may be fenestrated (11). It can show variations in its formation and termination too. A case of absence of retromandibular vein and formation of external jugular vein by union of superficial temporal and posterior division of maxillary vein has been reported (12). Occasionally, the external jugular vein communicates with the cephalic vein. The communicating vein passes superficial to clavicle and might bleed profusely in clavicular fractures (13). In the

present case, the external jugular vein was absent unilaterally.

Retromandibular vein is formed within the parotid gland and it divides into anterior and posterior divisions at the apex of the parotid gland. It may be completely absent (12) or remain undivided. In the current case the vein did not divide. Its position in relation to the facial nerve may also vary. In a study by Touré and Vacher (14), the vein was situated medial to the facial nerve in 65.2% cases and lateral to the nerve in 13% of cases.

Common facial vein also shows variations in its formation, termination and tributaries. In a study conducted by Bertha and Suganthy (15) the common facial vein drained into subclavian vein bilaterally in one specimen and into external jugular vein in 3 specimens. A case of looped common facial vein and an associated low formation of external jugular vein have also been reported (16). Though, there are many reports on variant formation and termination of common facial vein, there is no report on the formation of a thyro-linguo-facial trunk hitherto. We believe that the knowledge of this variation might be useful during surgery of submandibular salivary gland and also in carotid endarterectomy.

Conclusion

The present case is unique in having concurrent variations of sternocleidomastoid and veins of the neck. Though the presence of three headed sternocleidomastoid is common, presence of a thyro-linguo-facial trunk is extremely rare. Hence, knowledge of these variations could be of use to plastic surgeons, general surgeons and radiologists.

References

- Hasan T. Variations of the sternocleidomastoid muscle: a literature review. *The Internet Journal of Human Anatomy*. 2010; 2(1).
- Saha A, Mandal S, Chakraborty S, Bandyopadhyay M. Morphological study of the attachment of sternocleidomastoid muscle. *Singapore Med J* 2014; 55(1): 45-7.
- Rao TR, Vishnumaya G, Shetty PK, Suresh R. Variation in the origin of sternocleidomastoid muscle. A case report. *Int J Morphol* 2007; 25(3): 621-23.
- Kim SY, Jang HB, Kim J, Yoon SP. Bilateral four heads of the sternocleidomastoid muscle. *Surg Radiol Anat* 2014; 37(7): 871-3.
- Natsis K, Asouchidou I, Vasileiou M, Papatheanasiou E, Noussios G, Paraskevas G. A rare case of bilateral supernumerary heads of sternocleidomastoid muscle and its clinical impact. *Folia Morphol (Warsz)* 2009; 68(1): 52-4.
- Takahashi H, Umeda M, Sakakibara A, et al. Absence of the sternocleidomastoid muscle in a patient that underwent neck dissection for squamous cell carcinoma of the tongue. *Kobe J Med Sci* 2014; 59(5): E167-71.
- Nakajima M, Satomura H, Takahashi M, Muroi H, Kuwano H, Kato H. Effectiveness of sternocleidomastoid flap repair for cervical anastomotic leakage after esophageal reconstruction. *Dig Surg* 2014; 31(4-5): 306-11.
- Naghbizadeh M, Zojaji R, Mokhtari Amir Majdi N, Mazloun Farsi Baf M. Using a sternocleidomastoid muscle flap to prevent postoperative pharyngocutaneous fistula after total laryngectomy: a study of 88 cases. *Ear Nose Throat J* 2014; 93(8): 362-5.
- Demirci U, Basut O, Noyan B, et al. The efficacy of sternocleidomastoid muscle flap on frey's syndrome via a novel test: galvanic skin response. *Indian J Otolaryngol Head Neck Surg* 2014; 66(Suppl 1): 291-8.
- Wei D, Liu JH, Zhao WQ, Zhu HY, Li ZY, Wang HM. Use of the versatile sternocleidomastoid flap in oral and maxillofacial surgery: our experience. *Br J Oral Maxillofac Surg* 2013; 51(8): 742-6.
- Cvetko E. A case of left-sided absence and right-sided fenestration of the external jugular vein and a review of the literature. *Surg Radiol Anat* 2014; 37(7): 883-6.
- Patil J, Kumar N, Swamy RS, D'Souza MR, Guru A, Nayak SB. Absence of retromandibular vein associated with atypical formation of external jugular vein in the parotid region. *Anat Cell Biol* 2014; 47(2): 135-7.
- Nayak SB, Soumya KV. Abnormal formation and communication of external jugular vein. *International Journal of Anatomical Variations* 2008; 1: 15-16.
- Touré G, Vacher C. Relations of the facial nerve with the retromandibular vein: anatomic study of 132 parotid glands. *Surg Radiol Anat* 2010; 32(10): 957-61.

15. Bertha A and Suganthy Rabi. Anatomical variations in termination of common facial vein. *Journal of Clinical and Diagnostic Research* 2011; 5(1): 24-7.
16. Abhinitha P, Kumar N, Rao MKG, et al. An unusually looped common facial vein associated with low formation of external jugular vein. *Int J Clin Surg Adv* 2014; 2(3): 37-41.