

## Case Report

# Idiopathic Spontaneous Intraperitoneal Bleeding Secondary to Rupture of Short Gastric Artery

Kanmani M (✉), Soma BCK, Zairul Azwan R

Department of Surgery, Hospital Canselor Tuanku Muhriz, Universiti Kebangsaan Malaysia, Jalan Yaacob Latif, Bandar Tun Razak, 56000 Kuala Lumpur, Malaysia

### Abstract

Idiopathic spontaneous intraperitoneal bleeding (ISIH) is an uncommon surgical condition. Patients often present with various abdominal complaints, and it may mimic other common surgical pathologies. A high index of suspicion is needed to diagnose a patient presenting with this condition. We shared a case of ISIH secondary to a rupture of a short gastric artery in a previously healthy young man.

**Keywords:** Acute abdomen; hemoperitoneum; intraperitoneal bleeding; nontraumatic; short gastric artery

### Correspondence:

Dr Kanmani Murugesu. Department of Surgery, Hospital Canselor Tuanku Muhriz, Universiti Kebangsaan Malaysia, Jalan Yaacob Latif, Bandar Tun Razak, 56000 Kuala Lumpur, Malaysia. Tel: +6012-2046581 E-mail: kanmanimuruges@gmail.com

### Introduction

Idiopathic spontaneous intraabdominal haemorrhage (ISIH) or abdominal apoplexy (AA) is a term used to describe spontaneous non-traumatic intraperitoneal bleeding (1). It is commonly caused by spontaneous rupture of the splanchnic vessel with resultant intraperitoneal bleeding. The underlying pathophysiology is usually idiopathic; postulated causes are terminal vessel atherosclerosis and congenital anomaly (2). Bleeding from smaller visceral vessels is rare. We presented a peculiar case of bleeding from a short gastric artery.

### Case Report

A 30-year-old man with no known comorbidity presented with acute onset of upper abdominal pain for a day following a short history of cough. No prior history of abdominal trauma, vomiting, fever, respiratory tract infection symptoms, atopy history, or history of alcohol consumption. On initial assessment, he was lethargic, pale and in grade 2 hypovolemic shock. Fluid resuscitation was commenced immediately, to which he responded. Abdominal

examination revealed upper abdominal tenderness with localised guarding.

Biochemical assessment showed haemoglobin and blood gas of 11 g/dl and metabolic lactic acidosis, respectively. Chest and abdominal radiograph findings were not remarkable. Contrast computed tomography of the abdomen showed moderate free fluid in the perisplenic and pelvic regions. No obvious pneumoperitoneum or contrast blush (Figure 1).

Given persistent metabolic lactic acidosis and pain, the patient was counselled for exploratory laparotomy. Upon opening the abdomen, there was a moderate amount of hemoperitoneum, about 2 L of fresh blood, and the clot was evacuated. After packing and laparotomy assessment, it was noted there was active oozing of blood from the short gastric artery. The rest of the solid and hollow viscera were normal. The vessel was isolated, transfixed and ligated individually. The abdomen was washed thoroughly, and the abdominal drain was placed in the splenic bed. The postoperative period was rather uneventful; feeding was commenced shortly after the surgery, and he was discharged well on postoperative Day 3. He was well during the

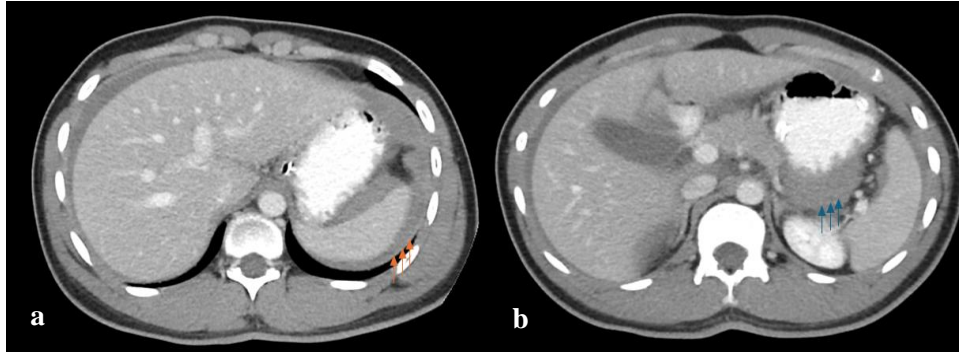


FIGURE 1(a) & (b): Contrast enhanced computed tomography of the abdomen shows free fluid at perisplenic (orange arrow) and lesser sac (blue arrow)

follow-up review in clinic 2 months later and was discharged from our care.

### Discussion

ISIH has been historically reported since 1909 (1). It is a rare condition and causes diagnostic dilemmas as the patient often presents with various symptoms, which include nonspecific abdominal pain and hemodynamic instability (3). It often mimics other conditions, such as acute pancreatitis, perforated peptic ulcer disease or even acute appendicitis (2,3).

Various causes of ISIH have been described in the literature, and commonly associated pathology are splanchnic vessel aneurysms and atherosclerosis in elderly patients. In younger groups of patients, congenital vessel anomaly or systemic vascular disease may give rise to this condition (3-5). The most involved site is the splenic artery, followed by the hepatic artery, superior mesenteric artery, gastric and gastroepiploic artery (2). ISIH involving small visceral arteries is rare, and up till now, there have been less than 20 reported cases caused by short gastric artery (SGA) rupture. Almost all reported cases were precipitated by episodes of vomiting or gagging. In 2016, Hong et al. (2016) compared 15 cases involving spontaneous bleeding from SGA. A total of 93% of the cases involved male patients, occurred in young adults and were preceded by vomiting (6).

Computed Tomography Angiography (CTA) and digital subtraction angiography are valuable investigations in diagnosing ISIH. It aids in localising the site of bleeding and subsequent angiographic management (6,7). Sometimes, results may be false negatives with no demonstrable extravasation (7). In our case, the contrasted CT abdomen showed free fluid in the left subphrenic and lesser sac with Hounsfield unit of (+42 to +52) and (+56 to 71+). No obvious

lesions were seen along the visceral vessels, and no contrast extravasation or pooling was seen in the delayed phase; hence, CTA was not done. Keeping ISIH as a differential diagnosis would change the type of imaging performed. In addition, angiographic intervention can be attempted (7).

Embolisation and surgery are the treatment options in these cases. Hong et al. (2016) reported a case in which the patient was treated conservatively with antifibrinolytic agent (tranexamic acid), Vitamin K and close monitoring (6,7). Conservative management hence possible in stable patients, however in unstable patients and if there is diagnostic dilemma surgery is inevitable.

### Conclusion

ISIH is a rare condition; however, delay in diagnosis can be fatal. Development in radiology leads to more opportunities to diagnose and treat non-surgically. ISIH should be suspected in patients presenting with acute abdomen, and prompt diagnosis is crucial for the management and positive outcome of this condition.

### References

1. Qaraqe TM, Abou Daher A, Alami RS. Abdominal apoplexy: A rare case of spontaneous middle colic artery rupture with transverse colectomy. *Int J Surg Case Rep* 2021; 81: 105835.
2. Osunkunle OA, Al-Shoek I. A case of abdominal apoplexy because of the rupture of the short gastric vessel. *J Surg Case Rep* 2015; 2015(3): rjv014.

3. McComb K, Barghash M, Eltayef S. Idiopathic spontaneous intraperitoneal haemorrhage (ISIH): A diagnostic dilemma and its conservative management. *Cureus* 2023; 15(9): e44879.
4. Negmadjanov U, Ohanisian L, Rubay D, Hristov B, Belizon A. Abdominal apoplexy: A case study of idiopathic spontaneous lesser sac hematoma. *Cureus* 2019; 11(6):e4937.
5. Zhou Y, Zhou Y, Li W, Lin S. Idiopathic spontaneous intraperitoneal hemorrhage due to vascular malformations in the muscularis of the stomach: A case report. *Front Med (Lausanne)*. 2022; 9: 927899.
6. Law EK, Lee RK, Hung EH, Ng AW. Radiological diagnosis and management of idiopathic spontaneous intra-abdominal haemorrhage (abdominal apoplexy): A case series. *Abdom Imaging* 2015; 40(2): 343-51.
7. Hong SW, Chang YG, Lee B, Lee WY. Spontaneous bleeding from a short gastric artery after vomiting successfully treated without surgery. *Korean J Gastroenterol* 2016; 68(3): 152-5.