

Kertas Asli/Original Articles

**Image Quality of Coronary CT Angiography (CCTA) using 640-slice Scanner:
Qualitative and Quantitative Assessments of Coronary Arteries Visibility**
(Kualiti Imej Tomografi Berkomputer Angiografi Koronari Menggunakan Mesin Pengimbas 640 Hirisan:
Penilaian Kualitatif dan Kuantitatif ke atas Keterlihatan Arteri Koronari)

SHAHRIIL SHAMSUL, AKMAL SABARUDIN, HAMZAINI ABDUL HAMID, NORZAILIN ABU BAKAR, OTEH MASKON &
MUHAMMAD KHALIS ABDUL KARIM

ABSTRACT

The purpose of this study was to evaluate the image quality and diagnostic accuracy of coronary computed tomography angiography (CCTA) using 640-slice scanner. Advancement of multidetector computed tomography (MDCT) technology with higher spatial, temporal resolution, and increasing detector array have improved the image quality and diagnostic accuracy of CCTA. A total of 25 patients (12 men and 13 women) underwent CCTA examination was chosen and data was acquired by 640-slice scanner. All 16 segments of coronary arteries were evaluated by two reviewers using a 4-likert scale for qualitative assessment. In quantitative assessment, the evaluation of 4 main coronary arteries were analysed in terms of signal intensity (SI), image noise, signal-to-noise ratio (SNR), and contrast-to-noise ratio (CNR). All 25 patients with a mean age of 52.88 ± 14.75 years old and body mass index (BMI) of 24.24 ± 3.28 kg/m² were analysed. In qualitative assessment, from the total of 400 segments, 379 segments (95%) had diagnostic value while 21 segments did not have diagnostic value, which means 5% artefact was detected. In quantitative assessment, there was no statistical differences in gender, race, and BMI ($p > 0.05$). Overall evaluation showed that higher SI at the left main artery (LM) at 393.7 ± 47.19 . Image noise was higher at right coronary artery (RCA) at 39.01 ± 13.97 . SNR and CNR showed higher at left anterior descending (LAD) with 12.73 ± 5.17 and LM 9.14 ± 4.2 , respectively. In conclusion, this study indicates that 640-slice MDCT has higher diagnostic value in CCTA examination with 95% vessel visibility with 5% artefact detection.

Keywords: CCTA; 640-slice scanner; coronary arteries; MDCT

ABSTRAK

Tujuan kajian ini adalah untuk menilai kualiti imej dan ketepatan diagnostik bagi pemeriksaan tomografi berkomputer angiografi koronari (CCTA) menggunakan mesin pengimbas 640 hirisan. Kemajuan teknologi dalam tomografi berkomputer berbilang hirisan dengan resolusi ruang dan masa yang tinggi serta susunan detektor yang canggih telah meningkatkan kualiti imej dan ketepatan diagnostik dalam CCTA. Sebanyak 25 pesakit (12 lelaki dan 13 wanita) telah dipilih untuk menjalani pemeriksaan CCTA menggunakan mesin pengimbas 640 hirisan. Semua 16 segmen arteri koronari telah dinilai oleh dua penilai menggunakan skala 4-likert untuk penilaian kualitatif. Dalam penilaian kuantitatif, penilaian 4 arteri koronari utama dianalisis dari segi intensiti isyarat, hingar imej, nisbah hingar-isyarat dan nisbah hingar-kontras. Kesemua 25 pesakit dengan min umur 52.88 ± 14.75 tahun dan indeks jisim tubuh 24.24 ± 3.28 kg/m² dianalisis. Dalam penilaian kualitatif, 379 daripada 400 segmen (95%) mempunyai imej bernilai diagnostik sementara 21 segmen tidak mempunyai nilai diagnostik dengan pengesanan artifak sebanyak 5%. Dalam penilaian kuantitatif, secara statistiknya, tidak ada perbezaan signifikan dalam jantina dan bangsa ($p > 0.05$). Keseluruhan penilaian menunjukkan bahawa intensity isyarat adalah lebih tinggi di arteri utama kiri pada 393.7 ± 47.19 . Hingar imej lebih tinggi pada arteri koronari kanan pada 39.01 ± 13.97 . Nisbah hingar-isyarat dan nisbah hingar-kontras direkodkan paling tinggi pada arteri menurun anterior kiri dan arteri utama kiri dengan masing-masing 12.73 ± 5.17 dan 9.14 ± 4.2 . Kesimpulannya, kajian ini menunjukkan bahawa mesin pengimbas 640 hirisan mempunyai nilai diagnostik yang lebih tinggi dalam pemeriksaan CCTA dengan keterlihatan arteri koronari sebanyak 95% dengan pengesanan artifak sebanyak 5%.

Kata kunci: CCTA, pengimbas hirisan berbilang 640, arteri koronari; tomografi berkomputer berbilang pengesan.

INTRODUCTION

Coronary artery disease (CAD) is the leading cause of morbidity and mortality in Malaysia. CAD can be defined as the coronary artery stenosis with lumen diameter reduction of at least 50% from their actual size (Raff et al. 2005). Early detection of CAD is important to reduce the morbidity and mortality rate. In the detection of CAD, invasive coronary angiography is known as the gold standard procedure with high sensitivity and specificity (Tan et al. 2016). However, this procedure is very much complicated since it involves admission into the hospital, high risk due to its invasive procedure, and also a costly procedure. Therefore, computed tomography (CT) has been used as an alternative to provide the diagnosis of CAD. Coronary computed tomography angiography (CCTA) has been introduced to overcome those issues and is in demand widely since it is a non-invasive anatomical assessment tool with high sensitivity (93%) and specificity (94%) in detecting CAD (Klass et al. 2009; Raff et al. 2005; Tan et al. 2016). CT technology has evolved rapidly since its introduction in the beginning of 1980's with electron beam CT (EBCT) in 1987 and multidetector CT (MDCT) in 1999 (Bijl et al. 2011; Budoff et al. 2006). Nowadays, the MDCT technology continues to develop from 4-slice to the recent 640-slice in order to achieve better spatial and temporal resolution so that more coronary segments available for evaluation (Nandurkar et al. 2009; Tan et al. 2016). The challenge of CCTA exists when it comes to the visualization of complex anatomy involving small coronary artery, tortuous coronary branches, and small diameter size (Jean Patrick 2014). Production of artefact is also one of the challenges in CCTA as it can cause degradation in image quality (Tan et al. 2016). There are two kinds of motion artefacts that usually influenced the quality of coronary artery image, which are the step and blurring artefacts (Sun et al. 2012). To solve this, MDCT with higher spatial and temporal resolutions, as well as wider detector array were developed, thus the entire heart can be acquired in single rotation by volumetric scan (Qin et al. 2012). This volumetric scan provides improvement of image quality, temporal uniformity, and reduction of artefacts (Rybicki et al. 2008). This advance development of MDCT technology allows CCTA to become a useful tool in the non-invasive anatomic assessment of CAD with high diagnostic accuracy (Bijl et al. 2011; Klass et al. 2009; Raff et al. 2005) in detecting CAD because it produces images with high spatial and temporal resolution (Takx et al. 2015) the number of evaluable segments, image quality, heart rate and blood pressure, and diagnostic accuracy of coronary computed tomography (CT). When newest features were introduced, the most important part needed to be

discussed is the image quality. To the best of our knowledge, the study of image quality CCTA using 640-slice scanner with CT volumetric scanning in combination of qualitative and quantitative analysis has yet to be reported. Thus, the purpose of this study was to evaluate the image quality of CCTA using 640-slice scanner with volumetric scan in terms of vessels visibility, diagnostic accuracy, and artefact detection.

MATERIALS AND METHODS

STUDY DESIGN AND POPULATION

This retrospective study was conducted at Hospital Canselor Tuanku Muhriz, Universiti Kebangsaan Malaysia Medical Centre (UKMMC) and data was collected from January to December 2018, which is since its operation started. Ethical approval was obtained from the institutional ethical committee (UKM PPI/111/8/JEP-2019-207). A total of 25 patients who underwent CCTA were selected as subject. Patients with higher calcium score, previous coronary artery bypass graft (CABG), primary pacemaker (PPM), and post percutaneous coronary intervention (PCI) were excluded from this study.

CORONARY CT ANGIOGRAPHY PROTOCOLS

The CCTA dataset were acquired using 640-slice scanner (Aquilion ONE, Toshiba Medical Systems, Otawara, Japan) which made up from a detector element consisting of 320×0.5 mm detector and provides 16 cm of coverage in the z direction. Images were acquired using prospective electrocardiogram (ECG)-gating with parameters as follows: tube voltage 120 kVp, auto exposure control (AEC) with maximum 600 mA, 350 ms of gantry rotation time, acquisition slice 0.5 mm with 0.5 mm interval, and ECG-gating set at 70 – 80% of R-R interval. No pitch was used in this study.

IMAGE ANALYSIS

The images were analysed through qualitative and quantitative assessments. Both assessments were evaluated using offline workstation (Vitrea 6.4, Vital Images, A Toshiba Medical Systems Group, Minnetonka, MN). Images were presented in axial views and reconstructed at 0.5 mm slice thickness. All images were reformed into oblique multiplanar reformation (MPR), curved multiplanar reformation (cMPR), and maximum intensity projection (MIP) for evaluation. The image evaluation system used in

this study was following the standard segmentation of 16 segments coronary arteries which consist of left main (LM), proximal left circumflex (pLCX), mid left circumflex (mLCX), distal left circumflex (dLCX), proximal left anterior descending (pLAD), mid left anterior descending (mLAD), distal left anterior descending (dLAD), proximal right coronary (pRCA), mid right coronary (mRCA), and distal right coronary (dRCA) for main segments. Meanwhile, the obtuse marginal 1 (OM1), obtuse marginal 1 (OM2), diagonal 1 (D1), diagonal 2 (D2), right posterior descending artery (R-PDA), and right posterolateral branch (R-PLA) were used for branches segment in line with the guidelines provided by the American Heart Association (Chian et al. 2017; Zhang et al. 2011) contrast volume and radiation dose at the 100-kilovolt (kV).

QUALITATIVE ANALYSIS

The qualitative assessment of image quality was performed by two independent reviewers (cardiologist) with certified experience in CCTA (more than 5 years). Both reviewers were blinded to all clinical information of dataset. The evaluation of subjective assessments of image quality was expressed by using 4-likert scale; score 1 indicated excellent quality without artefacts, score 2 indicated good quality with mild artefacts, score 3 indicated acceptable image quality with moderate artefacts, and score 4 indicated unevaluable quality with severe artefacts (Qin et al. 2012).

QUANTITATIVE ANALYSIS

The quantitative assessment was evaluated for 4 main coronary arteries which is LM, LCX, LAD and RCA. These assessment of image quality was determined by measuring

4 parameters which is signal intensity (SI), image noise, signal-to-noise ratio (SNR), and contrast-to-noise ratio (CNR) (Kojima et al. 2017). The measurements were performed on axial image of coronary arteries by one reviewer (radiographer). A fixed round shape region of interest (ROI) of 5 mm was placed into cardiac wall (A) and coronary arteries (B) to measure the Hounsfield unit (HU) as presented in Figure 1. SI was derived from the mean values of HU from two ROIs. Image noise can be defined as the mean standard deviation HU of SI. The SNR and CNR were calculated using the following formula:

$$SNR = \frac{SI}{N};$$

$$CNR = \frac{SICA - SICW}{N},$$

where SICA is SI at coronary artery and SICW is SI at the cardiac wall (Feuchtner et al. 2010; Jean Patrick 2014).

STATISTICAL ANALYSIS

Statistical analysis was performed using SPSS version 22.0 for Windows (SPSS Inc., USA). In qualitative assessment, data were expressed as frequencies or percentages and inter-observer agreement between two reviewers was analysed using Cohen's kappa statistics. For quantitative assessment, data were expressed as mean and standard deviation, otherwise p -value <0.05 was considered statistically significant. The comparison of image quality parameter among the gender, ethnicity and BMI classification was done using ANOVA.

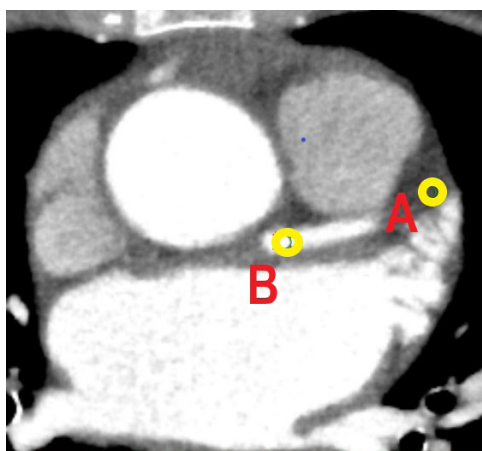


FIGURE 1. Region of interest (ROI) placement and measurement in coronary arteries and chest wall (cardiac wall mention as A and coronary arteries mention as B)

RESULT

All 25 datasets of coronary arteries image were successfully evaluated which consisted of 12 males and 13 females with mean age of 52.88 ± 14.75 years old. The mean body mass index (BMI), body weight, and height were 24.24 ± 3.28 kg/m², 65.92 ± 11.18 , and 164.72 ± 4.16 , respectively. Dataset was separated into 3 ethnicities which is Malay (52%), Chinese (36%) and Indian (12%).

A total of 400 segments were evaluated by two reviewers, in which 250 segments (62.5%) was identified as main vessels while 150 segments (37.5%) was identified as branches. The results showed that 236 segments (59%) were graded as excellent (scale 1), 112 segments (28%) were graded as good (scale 2), 31 segments (7.6%) were graded as acceptable (scale 3), and 21 segments (5.3%) were unevaluable image quality (scale 4). The images with diagnostic value were identified as graded 1, 2, and 3 score while score of 4 was identified as no diagnostic value. Total evaluation showed 378.5 segments have diagnostic value with 95% vessels visibility and only 21 segments don't have diagnostic value, which means 5% artefact was detected. The detailed evaluation is presented in Table 1 and overall evaluation score for both reviewers is presented

in Table 2. The kappa value shows excellent inter-reviewer agreements ($k = 0.94$) between 2 reviewers. For reviewer 1, graded image with diagnostic value was 280 (95%) and 20 images (5%) graded as no diagnostic value. For reviewer 2, the graded image with diagnostic value was 278 (94.5%) and 22 (5.5%) without diagnostic value.

Overall, the evaluation of objective assessment showed in Table 3. From the analysis, LM vessels showed higher SI (393.7 ± 47.19) and LCX vessels showed lower SI (358.72 ± 50.83). For noise parameter, the lowest noise found at LAD vessels which was at 34.87 ± 16.14 , while RCA shows the highest noise at 39.01 ± 13.97 . The higher results of SNR and CNR found in LAD vessels, which was 12.73 ± 5.17 for SNR and LM vessels at 9.14 ± 4.2 for CNR. Meanwhile, the RCA vessels shows the lowest results for SNR and CNR which were 10.32 ± 4.03 and 7.61 ± 3.58 , respectively.

The comparison shows no significant differences between gender, race, and BMI classification because p -value is more than 0.05. The comparison of quantitative image quality parameters between genders is presented in Table 4. The objective assessment results for comparison between three major ethnicities is shown in Table 5. While for the assessment among the BMI classification which is

TABLE 1. Overall evaluation of coronary arteries segment using qualitative assessment

Coronary arteries	Total N	Scale (score)				Diagnostic value		Visibility	Artefact
		1	2	3	4	Yes	No	%	%
All segment	400	236	112	31	21	379	21	95	5
Main vessels	250	236	14	0	0	250	0	100	0
Branches	150	0	98	31	21	129	21	86	14

TABLE 2. Overall evaluation of coronary arteries using qualitative assessment between two reviewers by using Likert-4 scale

No	Scale	Graded	Reviewer 1		Reviewer 2	
			N	%	N	%
1	Excellent	Diagnostic value	231	57.8	241	60.3
2	Good		119	29.8	106	26.5
3	Acceptable		30	7.5	31	7.8
4	Unevaluable	No diagnostic value	20	5	22	5.5

TABLE 3. Overall results of image quality for 4 main vessels by using quantitative assessment parameter (SI, Noise, SNR and CNR)

Vessels	SI	NOISE	SNR	CNR
LM	393.7 ± 47.19	38.0 ± 19.64	12.62 ± 5.58	9.14 ± 4.2
LCX	358.72 ± 50.83	38.92 ± 15.59	11.46 ± 7.08	8.87 ± 7.17
LAD	375.38 ± 50.07	34.87 ± 16.14	12.73 ± 5.17	8.73 ± 3.4
RCA	358.89 ± 63.27	39.01 ± 13.97	10.32 ± 4.03	7.61 ± 3.58

TABLE 4. Comparison of image quality parameter (SI, Noise, SNR and CNR) between male and female

Parameter	Male	Female	P-value
SI	352.92 ± 51.18	388.51 ± 38.26	0.22
NOISE	36.0 ± 11.33	39.26 ± 21.27	0.41
SNR	12.13 ± 4.82	11.46 ± 6.29	0.21
CNR	8.99 ± 3.33	8.21 ± 4.83	0.13

TABLE 5. Comparison of image quality parameter (SI, Noise, SNR and CNR) between ethnicity among Malay, Chinese and Indian

Parameter	Malay	Chinese	Indian	P-value
SI	369.96 ± 43.11	369.74 ± 38.26	384.92 ± 37.45	0.27
NOISE	34.63 ± 17.83	39.52 ± 22.67	45.51 ± 31.67	0.64
SNR	13.17 ± 4.66	10.41 ± 6.29	8.97 ± 4.33	0.48
CNR	9.87 ± 4.41	10.01 ± 4.83	7.96 ± 4.53	0.15

TABLE 6. Comparison of image quality parameter (SI, Noise, SNR and CNR) between BMI classification which is underweight, normal, overweight and obese

Parameter	Underweight	Normal	Overweight	Obese	P-value
SI	420.59 ± 55.13	372.24 ± 37.56	373.83 ± 35.12	321.31 ± 28.19	0.2
NOISE	47.35 ± 29.18	38.40 ± 21.34	36.76 ± 12.09	23.46 ± 9.34	0.44
SNR	9.55 ± 4.21	11.67 ± 5.43	11.86 ± 5.67	13.62 ± 4.88	0.16
CNR	5.62 ± 6.11	8.91 ± 4.11	8.28 ± 3.51	10.16 ± 4.92	0.12

underweight, normal, overweight, and obese is tabulated in Table 6.

DISCUSSION

This study highlighted four important findings in CCTA evaluation using 640-slice scanner. Firstly, this study found that 640-slice scanner provides further improved image quality in terms of vessels visibility. Secondly, we found that reduction of artefact can be achieved using 640-slice technology. Thirdly, this study produced better image quality in term of SNR and CNR parameters. Last finding showed that no significant difference in image quality among patients' gender, race, and BMI.

Firstly, 640-slice scanner provides further improved image quality in term of vessels visibility. The results show 95% visualization of coronary arteries vessels. This study proved that 640-slice scanner increased CCTA diagnostic accuracy as compared to previous study with lower slices scanner, with visualization of coronary arteries obtained at 87.3% (Pannu et al. 2006), 88% (Raff et al. 2005), 83% (Hoffmann et al. 2005), and 74.7% (Kuettner et al. 2005). The main reason in the improvement of coronaries arteries visualization is due to higher spatial and temporal resolution provided by 640-slice scanner when compared

to the previous generation of CT technology (Qin et al. 2012). The 640-slice scanner also used wide area of detector that allows image acquisition of the entire heart within a single gantry rotation and single heart beat (Fleur R. de Graaf et al. 2013) independent determinants of subsequent ICA and revascularization were evaluated. CTA studies were performed using a 64-row ($n = 413$). Despite of that, 640-slice scanner shows higher ability for the evaluation of main segments as compared to branches segment. These were proven by the excellent visualization score and good image quality was achieved only in main segments. The excellent and good image quality score (62.5%) comes from main segments while the other 5% score was contributed by unevaluable image quality found in branches segments. In line with study by Jean Patrick (2014), it was reported that the diagnostic accuracy of CCTA is lesser than other diagnostic tools when it is used for the evaluation of secondary segments. The finding was also supported by Nandurkar et al. (2009), which stated that MDCT has a higher ability to evaluate main vessels when compared to secondary segment of coronary artery. The reason of higher diagnostic score of main vessels is because of the size of main vessels which is larger, while unevaluable score is higher in branches segments due to the small size of coronary arteries. To increase the visualization of secondary branches, it is suggested to use

pre-medication such as nitrate to improve the visualization of small branches.

Secondly, we found that 640-slice scanner could reduce the production of artefact in coronary arteries. Generally, image artefacts are related to the limitations of temporal resolution (Sabarudin & Sun 2013). The most common reason of image quality degradation was motion artefact with 21% of segments were degraded by motion artefact (Tan et al. 2016). Only 5% of artefact presents in this study when compared to previous study which was 7.1% (Kuettner et al. 2005) and 12% (Fleur R. de Graaf et al. 2013) independent determinants of subsequent ICA and revascularization were evaluated. CTA studies were performed using a 64-row ($n = 413$). The factor that lowers the artefact production in this study is the recent technology in the 640-slice scanner with 16 cm volumetric data acquisition allowing entire cardiac scanning within a single gantry rotation which allows prospective ECG-gating. (Fleur R. de Graaf et al. 2013; Dewey et al. 2006) Nitrate [nitroglycerine], Nitrolingual N Spray. This type of scanning mode has eliminated helical acquisition artefact, pitch artefact, stair-step artefact, misregistration artefact, and motion artefact, therefore artefact produced are lower. Helical acquisition and pitch artefact were eliminated because of acquisition in single gantry rotation to cover entire heart in one heartbeat without table movement (Rybicki et al. 2008; van der Wall et al. 2012). Meanwhile, stair-step and misregistration artefact were eliminated due to sequential scanning or prospective ECG-gating used in this study (Nandurkar et al. 2009). In other hand, motion artefact that caused the blurring of image happens because of involuntary movement of coronary arteries. Thereby higher temporal resolution was beneficial in this study to eliminate the motion artefact, these 640-slice scanner (350 ms per gantry rotation) has slightly lower temporal resolution when compared to 64-MDCT (330 ms per gantry rotation) and dual source CT scanner (DSCT) (83 ms per gantry rotation). However, these 640-slice scanner used half scan reconstruction (175 ms per gantry rotation) in single gantry rotation with wide area coverage, unlike 64-MDCT and DSCT with small area coverage and require multiple gantry rotation to cover entire heart (F.R. de Graaf et al. 2010; van der Wall et al. 2012). Owing to that, the 640-slice scanner produces faster scanning time and has the ability to freeze cardiac motion. In order to optimize the production of artefact, it is suggested to control the heart rate to be in line with the principle of volumetric scan. The recommended heart rate is regular and lower than 65 bpm, so that the entire heart can be acquired in a single heartbeat without the degradation image quality.

Thirdly, in order to increase the diagnostic accuracy of coronary artery assessment, quantitative assessment

of image quality was done in this study. Quantitative assessment evaluated the SI, image noise, SNR and CNR as image quality parameter. Only 4 main vessels evaluated in this study without including segment branches, because ROI measurements were difficult and potentially less accurate for small branches of coronaries arteries (Karaca et al. 2007). The ROI size of 5 mm² was large enough for adequate pixel sampling and also small enough to affect non-uniformity of CT numbers, and because of that reason, small branches of coronary artery were not included in this objective assessment (Chian et al. 2017). Generally, with lower kVp setting, higher image noise will be produced and low contrast resolution will be increased (Feuchtner et al. 2010). However, this study used the same setting which is 120 kVp and because of that no significant difference between image noise in each segment was obtained. Hausleiter et al. (2006) reported that the increased SI will increase the image noise. However, it is not shown in this study as increasing SI did not increase the image noise. One of the factors that produce less image noise is the introduction of iterative reconstruction algorithms that was used in the system of this study, which is known as Adaptive Iterative Dose Reduction (AIDR). The AIDR is useful to reduce image noise while maintaining signal intensity and at the same time increasing SNR and CNR (Achenbach et al. 2017).

Heyer et al. (2007) stated that the best criteria for objective parameter of image quality is the determination of SNR and CNR. The SNR value of more than 10 is classified as a good image quality (Abada et al. 2006). While study by Karaca et al. (2007) stated that CNR can be classified into different grades which is CNR >8 indicates high image quality, 4 – 8 indicates moderate image quality, and <4 indicates poor image quality. This study shows that LM, LCX and LAD have the best image quality while the RCA shows moderate image quality. This is due to the anatomical position of coronary arteries. The LM, LCX and LAD are more proximal in anatomical position as compared to RCA and because of that the RCA have moderate image quality as compared to the other main vessels. Previous study by Yang et al. (2010) also stated that proximal anatomy segment has higher CNR over the distal segment of coronary arteries. The findings from this study is in line with previous study, whereby the RCA produces more motion artefact and more affected at higher heart rate. In contrast with previous study, this study found lower SNR and CNR as compared with study by Lee et al. (2019); and Yang et al. (2010). The possible explanation is the inadequate selection of ROI placement for bolus tracking, inadequate breath-holds, poor iterative reconstruction, and patient with higher BMI can result

in low SNR and CNR, resulting in poorly visualized coronary arteries (Yang et al. 2010).

The comparison of 4 main vessels with all quantitative parameters between male and female patients show no significant difference. However, this study found that the image noise in female is higher than male. Previously, Yoshimura et al. (2006) reported that image noise did not significantly correlates with BMI in males, whereas image noise showed excellent correlation with BMI in females. This is due to the difference size in chest area and also weight composition in female rather than male. The comparison of image quality between 3 major races shows no significant difference because all races showed almost same characteristic in body habitus. There are no previous studies that reported on the differences in quality of image over race but the body habitus among races was studied. Due to body habitus reason, this study used tube current modulation to allow automatic selection for the most appropriate tube potential and the mAs setting according to the patient's body habitus (H.S. Lee et al. 2018). However, results produced were not consistent and has variable measurement of SI, image noise, SNR and CNR. Therefore this study agreed with previous statement by Wang et al. (2018) which stated that tube current modulation method in coronary CTA was not able to achieve consistent objective image quality across the entire patient population. The last comparison of objective assessment found no significant difference between the BMI classification. Previous study found that, image noise was correlated with biometric data which is BMI (Yoshimura et al. 2006). Greater BMI are associated with higher image noise, thus reducing SNR and CNR, and negatively affects the quality of CCTA (Yang et al. 2010). However, results from this study challenges the statement of previous study, where it shows variable and uneven readings. The discrepancy may be due to implementation of ECG-tube current modulation, automatic tube potential selection, and iterative reconstruction (J. Lee et al. 2019). In addition, the placement of ROI also affects the result of image quality as mentioned in previous study, in which the placement of ROI is important in obtaining accurate measurements (Chian et al. 2017).

There were several limitations in this study. Firstly, the number of patients recruited in this study was small due to being conducted at one institution. A larger sample size, preferably at multi-centre sites are desirable for future studies. Secondly, the accuracy of ROI measurement in objective analysis is questionable since the measurement was only performed by single person, even though the measurement was taken twice for each ROI to reduce uncertainties.

CONCLUSION

In conclusion, this study shows that the 640-slice scanner with wide area of detector produces higher CCTA image quality in terms of qualitative and quantitative assessments.

ACKNOWLEDGEMENTS

We would like to thank the radiographers from Department of Radiology, Hospital Canselor Tuanku Muhriz, Universiti Kebangsaan Malaysia Medical Centre (UKMMC), especially who work at the CT Scan unit for the assistance during data collection.

REFERENCES

- Abada, H.T., Larchez, C., Daoud, B., Sigal-Cinqualbre, A. & Paul, J.-F. 2006. MDCT of the Coronary Arteries: Feasibility of Low-Dose CT with ECG-Pulsed Tube Current Modulation to Reduce Radiation Dose. *American Journal of Roentgenology* 186(6_supplement_2): S387–S390. doi:10.2214/AJR.05.0216.
- Achenbach, S., Paul, J., Laurent, F., Becker, H., Rengo, M., Caudron, J., Leschka, S., et al. 2017. Comparative assessment of image quality for coronary CT angiography with iobitridol and two contrast agents with higher iodine concentrations: iopromide and iomeprol. A multicentre randomized double-blind trial. *European Radiology* 27(2): 821–830. doi:10.1007/s00330-016-4437-9.
- Bijl, N. van der, Geleijns, J., Joemai, R.M., Bax, J. J., Schuijff, J.D., Roos, A. de & Kroft†, L.J. 2011. Recent developments in cardiac CT. *Journal belge de radiologie* 3(2): 167–192.
- Budoff, M.J., Achenbach, S., Blumenthal, R.S., Carr, J.J., Goldin, J.G., Greenland, P., Guerci, A.D. et al. 2006. Assessment of Coronary Artery Disease by Cardiac Computed Tomography. *Circulation* 114(16): 1761–1791. doi:10.1161/CIRCULATIONAHA.106.178458.
- Chian, T.C., Nassir, N.M., Ibrahim, M.I., Yusof, A.K.M. & Sabarudin, A. 2017. Quantitative assessment on coronary computed tomography angiography (CCTA) image quality: comparisons between genders and different tube voltage settings. *Quantitative Imaging in Medicine and Surgery* 7(1): 48–58. doi:10.21037/qims.2017.02.02.
- de Graaf, F.R., Schuijff, J.D., van Velzen, J.E., Kroft, L.J., de Roos, A., Reiber, J.H.C., Boersma, E., et al. 2010. Diagnostic accuracy of 320-row multidetector computed tomography coronary angiography in the non-invasive evaluation of significant coronary artery disease. *European Heart Journal* 31(15): 1908–1915. doi:10.1093/eurheartj/ehp571.

- de Graaf, Fleur R., van Velzen, J.E., de Boer, S.M., van Werkhoven, J.M., Kroft, L.J., de Roos, A., Sieders, A., et al. 2013. Non-invasive computed tomography coronary angiography as a gatekeeper for invasive coronary angiography. *The International Journal of Cardiovascular Imaging* 29(1): 221–228. doi:10.1007/s10554-012-0059-8.
- Dewey, M., Hoffmann, H. & Hamm, B. 2006. Multislice CT coronary angiography: Effect of sublingual nitroglycerine on the diameter of coronary arteries. *RöFo - Fortschritte auf dem Gebiet der Röntgenstrahlen und der bildgebenden Verfahren* 178(6): 600–604. doi:10.1055/s-2006-926755.
- Feuchtnner, G.M., Jodocy, D., Klauser, A., Haberkeller, B., Aglan, I., Spoeck, A., Hiehs, S., et al. 2010. Radiation dose reduction by using 100-kV tube voltage in cardiac 64-slice computed tomography: A comparative study. *European Journal of Radiology* 75(1): e51–e56. doi:10.1016/j.ejrad.2009.07.012.
- Hausleiter, J., Meyer, T., Hadamitzky, M., Huber, E., Zankl, M., Martinoff, S., Kastrati, A., et al. 2006. Radiation Dose Estimates From Cardiac Multislice Computed Tomography in Daily Practice Impact of Different Scanning Protocols on Effective Dose Estimates. doi:10.1161/CIRCULATIONAHA.105.602490.
- Heyer, C.M., Mohr, P.S., Lemburg, S.P., Peters, S.A. & Nicola, V. 2007. Image Quality and Radiation Exposure at Pulmonary CT Angiography with 100- or Methods Results : Conclusion : 245(2): 577–583.
- Hoffmann, M.H.K., Shi, H., Manzke, R., Schmid, F.T., Vries, L. De, Grass, M. & Aschoff, A.J. 2005. Noninvasive Coronary Angiography with 16-Detector Row CT: Effect of Heart Rate 1(7).
- Jean Patrick, D. 2014. Effect of sublingual nitroglycerine premedication on image analysis of using 256 multidetector computed tomography coronary angiography. *OMICS Journal of Radiology* 02(04). doi:10.4172/2167-7964.1000173
- Karaca, M., Kirilmaz, A., Oncel, G., Oncel, D., Yilmaz, H. & Gurcay, B. 2007. Contrast-Enhanced 64-Slice Computed Tomography in Detection and Evaluation of Anomalous Coronary Arteries 249–259.
- Klass, O., Mutlu, S., Hohl, K., Feuerlein, S., Jeltsch, M., Brambs, H. J. & Hoffmann, M. H. K. 2009. Multidetector computed tomography coronary angiography: Sublingual nitroglycerine improves image quality significantly because of peripheral coronary vasodilatation. *Journal of Computer Assisted Tomography* 33(2): 199–203. doi:10.1097/RCT.0b013e31817c6b33.
- Kojima, T., Suzuki, D., Hoshika, M., Togami, I., Nishiyama, N., Niguma, T. & Yasui, K. 2017. Novel contrast-injection protocol for high-resolution abdominal CT-angiography: vascular visualization improvement with vasodilator. *Abdominal Radiology* 42(10): 2571–2578. doi:10.1007/s00261-017-1163-y.
- Kuettner, A., Beck, T., Drosch, T., Kettering, K., Heuschmid, M., Burgstahler, C., Claussen, C. D., et al. 2005. Diagnostic Accuracy of Noninvasive Coronary Imaging Using 16-Detector Slice Spiral Computed Tomography With 188 ms Temporal Resolution. *Journal of the American College of Cardiology* 45(1): 123–127. doi:10.1016/j.jacc.2004.10.050.
- Lee, H.S., Suh, Y.J., Han, K., Kim, J.Y., Chang, S., Im, D.J., Hong, Y.J., et al. 2018. Effectiveness of automatic tube potential selection with tube current modulation in coronary CT angiography for obese patients: Comparison with a body mass index-based protocol using the propensity score matching method. (O. R. Coelho-Filho, Ed.) *PLOS ONE* 13(1): e0190584. doi:10.1371/journal.pone.0190584.
- Lee, J., Kim, T.H., Lee, B.K., Yoon, Y.W., Kwon, H.M., Hong, B.K., Min, P., et al. 2019. Diagnostic accuracy of low-radiation coronary computed tomography angiography with low tube voltage and knowledge-based model reconstruction (December 2018): 1–9. doi:10.1038/s41598-018-37870-3.
- Nandurkar, D., Cameron, J.D., Crossett, M., Schneiderkolsky, M.E., Troupis, J.M., Ss, P., Nandurkar, D., et al. 2009. Image Quality of Coronary 320-MDCT in Patients With Atrial Fibrillation : Initial Experience (December): 1514–1521. doi:10.2214/AJR.09.2319.
- Pannu, H.K., Jacobs, J.E., Lai, S. & Fishman, E.K. 2006. Coronary CT angiography with 64-MDCT: Assessment of vessel visibility. *American Journal of Roentgenology* 187(1): 119–126. doi:10.2214/AJR.05.0908.
- Qin, J., Liu, L.-Y., Fang, Y., Zhu, J.-M., Wu, Z., Zhu, K.-S., Zhang, J.-S., et al. 2012. 320-detector CT coronary angiography with prospective and retrospective electrocardiogram gating in a single heartbeat: comparison of image quality and radiation dose. *The British Journal of Radiology* 85(1015): 945–951. doi:10.1259/bjr/29901700.
- Raff, G.L., Gallagher, M.J., O'Neill, W.W. & Goldstein, J.A. 2005. Diagnostic accuracy of noninvasive coronary angiography using 64-slice spiral computed tomography. *Journal of the American College of Cardiology* 46(3): 552–557. doi:10.1016/j.jacc.2005.05.056.
- Rybicki, F.J., Otero, H.J., Steigner, M.L., Vorobiof, G., Nallamshetty, L., Mitsouras, D., Ersoy, H., et al. 2008. Initial evaluation of coronary images from 320-detector row computed tomography 535–546. doi:10.1007/s10554-008-9308-2.
- Sabarudin, A. & Sun, Z. 2013. Coronary CT angiography: Diagnostic value and clinical challenges. *World journal of cardiology* 5(12): 473–483. doi:10.4330/wjc.v5.i12.473.
- Sun, G., Li, M., Jiang, X.-S., Li, L., Peng, Z.-H., Li, G.-Y. & Xu, L. 2012. 320-detector row CT coronary angiography: effects of heart rate and heart rate

- variability on image quality, diagnostic accuracy and radiation exposure. *The British Journal of Radiology* 85(1016): e388–e394. doi:10.1259/bjr/92160185.
- Takx, R.A.P., Suchá, D., Park, J., Leiner, T. & Hoffmann, U. 2015. Sublingual Nitroglycerin Administration in Coronary Computed Tomography Angiography: a Systematic Review. *European Radiology* 25(12): 3536–3542. doi:10.1007/s00330-015-3791-3.
- Tan, S.K., Yeong, C.H., Ng, K.H., Abdul Aziz, Y.F. & Sun, Z. 2016. Recent Update on Radiation Dose Assessment for the State-of-the-Art Coronary Computed Tomography Angiography Protocols. (L. Dubois, Ed.) *PLOS ONE* 11(8): e0161543. doi:10.1371/journal.pone.0161543.
- van der Wall, E.E., de Graaf, F.R., van Velzen, J.E., Jukema, J.W., Bax, J.J. & Schuijff, J.D. 2012. 320-row CT: does beat-to-beat motion of the coronary arteries affect image quality? *The International Journal of Cardiovascular Imaging* 28(1): 147–151. doi:10.1007/s10554-010-9794-x.
- Wang, X.P., Zhu, X.M.E.I., Zhu, Y.I.N.S.U., Liu, W.Y.A.N. & Yang, X.H.A.N. 2018. Automatic tube potential selection with tube current modulation in coronary CT angiography : Can it achieve consistent image quality among various individuals ? 253–259. doi:10.3892/etm.2018.6158.
- Yang, L., Wu, D., Chen, C., Liu, G., Hsieh, T., Jaw, T., Huang, S., et al. 2010. 64- slice - computed tomography of coronary arteries in subjects undergoing screening. *The Kaohsiung Journal of Medical Sciences* 26(1): 21–29. doi:10.1016/S1607-551X(10)70004-8.
- Yoshimura, N., Sabir, A., Kubo, T., Lin, P.P., Clouse, M.E. & Hatabu, H. 2006. Correlation Between Image Noise and Body Weight in Coronary CTA with 16-row MDCT 1 (11): 324–328. doi:10.1016/j.acra.2005.11.036.
- Zhang, C., Zhang, Z., Yan, Z., Xu, L., Yu, W. & Wang, R. 2011. 320-row CT coronary angiography: effect of 100-kV tube voltages on image quality, contrast volume, and radiation dose. *The International Journal of Cardiovascular Imaging* 27(7): 1059–1068. doi:10.1007/s10554-010-9754-5.

Shahril Shamsul
Akmal Sabarudin
Diagnostic Imaging & Radiotherapy Program
Faculty of Health Sciences
Universiti Kebangsaan Malaysia
50300, Kuala Lumpur
Malaysia

Hamzaini Abdul Hamid
Norzailin Abu Bakar
Department of Radiology
Faculty of Medicine
UKM Medical Center
Jalan Yaacob Latif, Bandar Tun Razak
56000 Kuala Lumpur
Malaysia

Oteh Maskon
Department of Cardiology
Faculty of Medicine, UKM Medical Center
Jalan Yaacob Latif, Bandar Tun Razak
56000 Kuala Lumpur
Malaysia

Muhammad Khalis Abdul Karim
Department of Physics
Universiti Putra Malaysia (UPM)
Serdang, 43400, Selangor Darul Ehsan
Malaysia

Corresponding author:

Assoc. Prof. Dr. Akmal Sabarudin
Phone: +603 9289 7641
Fax: +603 2692 9032
Email: akmal.sabarudin@ukm.edu.my

