



The Effects of *Carica papaya* Linn. Latex on the Healing of Burn Wounds in Rats

AHMAD NAZRUN SHUID, MOHD SYUKRI ANWAR &
AHMAD ASMADI YUSOF

ABSTRAK

Kajian ini bertujuan untuk membandingkan masa penyembuhan luka bakar apabila dirawat dengan getah Carica papaya Linn. (betik) atau krim 'silver sulfadiazine' (SSD). Plat logam yang dipanaskan digunakan untuk menghasilkan luka bakar tebal separa dan penuh (2 cm x 2 cm) pada bahagian dorsal tikus yang dibius. Tikus dibahagi kepada tiga kumpulan, iaitu kumpulan yang tidak dirawat dan kumpulan yang masing-masing dirawat setiap hari dengan SSD dan getah betik. Kamera digital digunakan untuk mengambil gambar luka bakar setiap hari untuk menilai penyembuhan luka bakar. Kajian ini mendapati tiada perbezaan signifikan antara masa penyembuhan kumpulan rawatan getah betik dan SSD. Getah betik mengandungi enzim penghadam yang boleh membersihkan luka dan mungkin telah menyebabkan pendarahan luka pada beberapa tikus kumpulan rawatan getah betik.

Kata kunci: Carica papaya Linn., getah betik, tikus, luka bakar, silver sulfadiazine

ABSTRACT

This study was carried out to compare the rate of burn wound healing with the applications of the latex of Carica papaya Linn. (papaya) or of silver sulfadiazine cream (SSD). Partial and full thickness burn wound (2 cm x 2 cm) was induced on the dorsal part of anaesthetized rats by using heated metal plates. The rats were divided into three groups, i.e. untreated group and groups treated daily with SSD and papaya latex, respectively. A digital camera was used to take photographs of the burn wounds daily to monitor their healing. It was found that there was no significant difference in the healing time of papaya latex treated group compared to the SSD treated group. Papaya latex contained digestive enzymes which might clean burn wounds but might also cause wound bleeding in a few rats of the papaya latex group.

Keywords: Carica papaya Linn., papaya latex, rats, burn wound, silver sulfadiazine



INTRODUCTION

Burn wound is an injury, especially to the skin by fire, heat, radiation, electricity or caustic agents (Chandrosama & Taylor 1998). It can be classified into epidermal, partial thickness and full thickness burn wound. Epidermal burn wound involves only the epidermal layer of the skin, partial thickness involve the epidermal and dermal layer of the skin, while a full thickness involves the subcutaneous layer of the skin. Burn wound is a major health issue in developing countries (Heimbach 1999). Burn wound causes disruption of the skin's mechanical integrity and allows environmental microbes to cause infection and delay wound healing. The incidence of burn wound infection is directly related to the extent of the burn. Systemic infection resulting from burn wound infection is the main cause of death among patients who are hospitalized for burns.


In modern setting, uncomplicated burn wound is treated with wound debridement and silver sulfadiazine cream (SSD) (Mani 2002). The purpose of wound debridement is to remove necrotic tissue and eschar that foster microbial growth and burn wound infection. SSD has broad spectrum antimicrobial activities. It has been shown to inhibit bacteria that are resistant to other antimicrobial agents. Although SSD has been the standard treatment of burn wound in the hospital, alternative treatment for burn wound that is cheaper and locally available is still practiced. According to the traditional practice in Malaysia, latex from *Carica papaya* Linn. (papaya) when applied to burn wound could promote healing and reduce scar formation (Ayob 2003). Papaya trees can easily be found in tropical countries. Its stem, leaves and fruits are abundant in latex which is rich in digestive enzymes papain, chymopapain and leukopapain. It also contains the alkaloidal compound, carpaine (Starley et al. 1999). The digestive enzymes can digest the slough and clean the wound while carpaine has shown antibacterial activities (Martinian et al. 1990; Heinerman 1988). In West Africa, papaya leaves have been used to treat burn wound (Martin 1996). In Jamaica, papaya latex has been shown to be an effective debriding and healing agent in pressure ulcer (Hewitt et al. 2002).

There has been no report on the effectiveness of papaya latex in treating burn wound as compared to the standard modern treatment. Therefore, in this study, we compared the healing times of both partial and full thickness burn wounds in rats that received papaya latex treatment or the standard SSD treatment.

MATERIALS AND METHODS

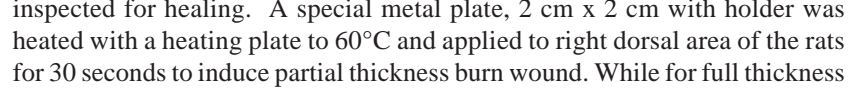
PREPARATION OF SAMPLES

A total of 18 Sprague Dawley male rats weighing between 250-350 g, were acclimatized into the surrounding for a week. Each rat was caged individually



and rat chow and water were given *ad libitum*. The rats were divided into three groups with 6 rats in each group and burn wounds were induced on all the rats according to the method by Paramonov and Chebotarev (2002). A small area (2 cm x 2 cm) of full and partial thickness burn wounds were induced on the left dorsal area and right dorsal area of each rat. This would represent a burn wound model with mixed full and partial thickness burn wound. This would also allow comparison of the healing rate between the full and partial thickness burn wounds in the same rat. The first group received no treatment for the burn wound and acts as the control group, the second group was treated with SSD while the third group was treated with fresh papaya latex obtained from *Carica papaya*. Fresh papaya leaves were cut at various places and the latex that oozed out were collected into a test tube. About 5 ml of papaya latex were collected daily for application to the burn wounds. The study method was approved by the Universiti Kebangsaan Malaysia (UKM) Animal Ethics Committee.

PROCEDURE



The rats were anesthetized with ether and the dorsal areas of the rats were shaved. Dorsal side was chosen as this area was not reachable by the rats and therefore the wound healing was not disturbed. This area could also be easily inspected for healing. A special metal plate, 2 cm x 2 cm with holder was heated with a heating plate to 60°C and applied to right dorsal area of the rats for 30 seconds to induce partial thickness burn wound. While for full thickness burn wound, the metal plate was heated to 100°C and the same procedure was repeated on the left dorsal area. For the treated groups, the papaya latex obtained from fresh papaya leaves of *Carica papaya* at dose of 500 mg (0.4 ml) or 1% SSD at dose of 500 mg was applied once daily to the burn wounds until they are fully healed. Excess amount of papaya latex or SSD were applied to make sure that they fully covered the burn wounds. The study lasted for 34 days when the burn wounds of all the rats have healed. The healing of the burn wounds was monitored with a digital camera (Sony Cybershot DSC-P72) until they were healed. Images of the burn wounds were taken daily to determine the time taken to heal for each of the group. The amount of water and rat chow taken were also measured daily.

STATISTICAL ANALYSIS

Data was analyzed using the Statistical Package for Social Sciences Software (SPSS). The results were presented as mean \pm standard error of the mean (SEM). ANOVA was used with Tukey's honestly significant difference as the post-hoc test.

RESULTS AND DISCUSSION

There was no significant difference in healing time of the burn wounds for all the groups for both partial and full thickness burn (Figure 1). Therefore, applications of 1% SSD or papaya latex to burn wounds were not able to reduce healing time when compared to the control group. However, a few rats in the papaya latex group were observed to develop wound bleeding. On inspection, the wounds were found to be clean and not infected but the healing time were prolonged (Plate 1). There was no significant difference in daily water intake for all the groups. However, there was a significant reduction of rat chow intake at week 2 and week 4 compared to week 1 for SSD group (Figure 2). There was no significant difference in rat chow intake for the control group or papaya latex group.

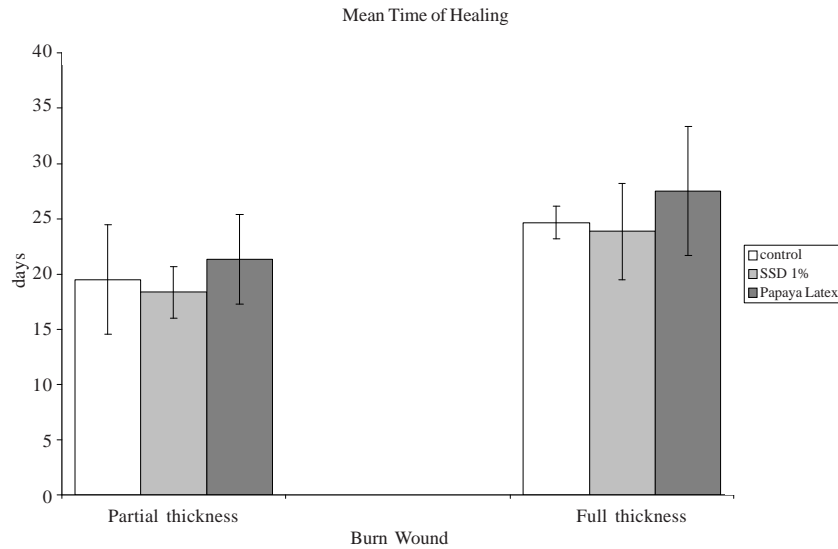



FIGURE 1. The healing time of burn wounds for partial and full thickness burn in rats.

The standard treatment of burns in most hospital has been by covering the burn wound with silver sulfadiazine cream (SSD) which acts as an antibacterial agent (Jackson 1991). In some developing countries, papaya latex has been used traditionally for treatment of burn wounds (Ayob 2003). In this study, there was no difference in the healing time of burn wounds of the rats when treated with 1% SSD or papaya latex. As expected, SSD did not reduce the healing time of burn wounds as compared to the control group (untreated). The wounds in the papaya latex group were found to be uninfected and clean as the SSD group. However, wound bleeding was observed in a few rats treated with papaya latex. We believe this might be due to digestive properties of the enzymes found in papaya latex.







* indicate significantly different from week 1 rat chow intake for SSD group. ($p < 0.05$). The reduction in rat chow intake at week 2 and 4 for papaya latex group were not significantly different from week 1 ($p = 0.05$).

FIGURE 2. Daily rat chow intake for papaya treated, SSD and control groups

These rats were found to have longer healing time which prolonged the mean healing time for the papaya latex group although not significantly different from the control or SSD groups.

In burn wound injuries, the usual skin barrier is replaced by moist, protein-rich, avascular eschar that fosters microbial growth. Wound debridement to remove the eschar and necrotic tissues has been part of burn wound management to prevent infection and promote wound healing. Papain is an enzyme used commercially to soften meat and has the ability to digest dead tissues (Hewitt et al. 2002). Papain may therefore help digest the eschar and necrotic tissues and reduce the need for the painful manual wound debridement for burn wound. A study on the use of similar enzyme on burn wound management has been conducted. Collagenase, an exogenous enzyme was used for burn wound debridement and was found to accelerate wound cleaning and healing compared to SSD (Hansbrough et al. 1995). The burn wounds treated with collagenase were found to be free of retained debris and have shorter time of healing. Papain which might be present in the papaya latex could be responsible for producing less scarring of the burn wounds as it produced cleaner wounds.

We observed a reduction in rat chow intake at week 2 and 4 for SSD group when compared to week 1 ($p < 0.05$) (Figure 2). Food intake reduction and weight loss in rats have been associated with pain (McKenzie et al. 2004; Kohn et al.



1997). SSD treatment has been reported to cause more pain compared to other medications, like hydrocolloid dressing, biothane and phenytoin (Wyatt et al. 1990; Gerding et al. 1990; Hansbrough 1995). As all the rats were exposed to the same environment, the rats receiving SSD might be experiencing pain which led to the reduction of food intake. On the other hand, papaya latex might not have caused pain when applied to the burn wounds as the food intake was not affected.

Our future study would be to determine the optimal amount and dosage of papaya latex which may promote healing of burn wound without causing bleeding of the burn wound. We would also like to look at the ability of papaya latex to clean burn wound and cause less scar by histological analysis. We believe that SSD has a broader spectrum of anti-bacterial activities, but papaya latex may have the advantages of providing a less painful treatment, producing a cleaner and scar less burn wound.

REFERENCES

- Ayob Ismail. 2003. *Khazanah Herba- Dalam Koleksi Perubatan Tradisional Yang Hebat dan Petua Orang Tua*. Hlm 86. Golden Book Centre.
- Carneiro, P.M., Rwanyuma, L.R. & Mkony, C.A. 2002. A comparison of topical Phenytoin with Silverex in the treatment of superficial dermal burn wounds. *Cent. Afr. J. Med.* 48(9-10): 105
- Chandrasoma, R & Taylor, C.R. 1998. *Healing and repair In Concise Pathology*. 3rd Ed. London. Prentice Hall International Inc.
- Gerding, R.L., Emerman, C.L. Efron, D., Lukens, T., Imbembo, A.L. & Fratianne, R.B. 1990. Outpatient management of partial-thickness burns: Biobrane versus 1% silver sulfadiazine. *Ann. Emerg. Med.* 19(2): 121-124.
- Hansbrough, J.F., Achauer, B., Dawson, J., Himel, H., Luterman, A., Slater, H., Levenson, S., Salzberg, C.A., Hansbrough, W.B. & Dore, C.. 1995. Wound healing in partial-thickness burn wounds treated with collagenase ointment versus silver sulfadiazine cream. *J. Burn Care Rehabil.* 16: 241- 247.
- Heimbach, D.. 1999. Burn patient then and now. *Burns.* 25: 1-2
- Heinerman, J. 1988. *Heinerman's Encyclopedia of Fruits, Vegetable and Herbs*. Upper Sadle River (N.J.). Prentice Hall International Inc.
- Hewitt, H., Wint, Y., Tolobere, L., Lopez, S., Bailey, E., Parshad, O. & Weaver, S. 2002. The use of papaya on pressure ulcers. *Am. Jour. Nutr.* 102(12): 73-77.
- Jackson, D.M. 1991. The evolution of burn treatment in the last 50 years. *Burns.* 17: 329-334.
- Kohn, W. & White, B.1997. *Guidelines for recognition of pain Anesthesia and Analgesia in Laboratory Animals*; (eds); Academic Press. Inc.
- Mani, R. 2002. *Chronic Wound Management*. London. Taylor and Francis Group.
- Martinian, L.A., Nahapetian, K.H., Mirzoyan, V.S. & Bagdassarian, R.V. 1990. Effects of leucopapaine on the process of purulent wound repairing in experiments and clinical cases. *Act. Physiol. Pharm. Bulg.* 1: 76-81.



- Martin, A. 1996. The use of antioxidant in healing. *Dermatol. Surg.* 22: 156-160.
- McKenzie, D.A., Paquet, C., Kergoat, M.J., Ferland, G. & Dubé, L. 2004. Hunger and Aversion: Drives That Influence Food Intake of Hospitalized Geriatric Patients. *J. Gerontol. Series A: Biol. Sci. Medic. Sc.* 59: 1304-1309.
- Paramonov, V.A. & Chebotarev, V.Y. 2002. Modeling of thermal skin injury for the development of local treatment drugs. *Bull. Exp. Biol. Med.* 134 (5): 512-515.
- Starley I.F., Mohammed, P., Schneider G., Bicckler, S.W. 1999. The treatment of paediatric burns using topical papaya. *Burns* 25(7): 633-639.
- Wyatt, D., McGowan, D.N. & Najarian, M.P. 1990. Comparison of a hydrocolloid dressing and silver sulfadiazine cream in the outpatient management of second-degree burns. *J. Trauma* 30(7): 857-865.

Ahmad Nazrun Shuid
Ahmad Asmadi Yusof
Pharmacology Department
Faculty Medicine
Universiti Kebangsaan Malaysia
Jalan Raja Muda Abdul Aziz
50300 Kuala Lumpur

Mohd Syukri Anwar
Biomedical Science Department
Faculty of Allied Health Sciences
Universiti Kebangsaan Malaysia
Jalan Raja Muda Abdul Aziz
50300 Kuala Lumpur