

Kertas Asli/Original Articles

CT VS MR Attenuation Correction: A Systematic Review on PET Image Quality Assessment

(Kaedah Pembetulan Pengecilan Menggunakan Data CT dan MR: Kajian Sistematis terhadap Penilaian Kualiti imej PET.)

RUKIAH A LATIFF*, MOHD IZUAN IBRAHIM, MOHAMMAD AIZART ROSLI & NUR FARAHANA NAJWA ELYAS YEOW

ABSTRACT

This systematic review was conducted to evaluate the image quality performance when implementing computed tomography data (CTAC) or magnetic resonance data for attenuation correction (MRAC) on positron emission tomography (PET) images. The CTAC and MRAC were performed on image from PET/CT and PET/MR scanners, respectively. The systematic review was done based on Preferred Reporting Items for Systematic Reviews (PRISMA). In this study, twelve articles were included from six databases. The image performance was evaluated by overall image quality, contrast, spatial resolution, detectability, standardised uptake value (SUV) and acquisition time. Data was shown as mean \pm standard deviation and compared between CTAC and MRAC images to determine which attenuation correction method provides better image quality. Results found that PET-CTAC and PET-MRAC have similar image performance in overall image quality ($p=0.93$), detectability ($p=0.84$), SUV_{mean} ($p=0.84$) and SUV_{max} ($p=0.81$). Meanwhile, PET-CTAC acquisition time is significantly faster than PET-MRAC by approximately two fold ($p < 0.05$). There were no statistical analyses performed for image contrast, spatial resolution and contrast-noise-ratio due to the insufficient data. In conclusion, although PET/CT is faster than PET/MRI procedure, images yielded from CTAC and MRAC are equivalent to each other. Due to the variation of linear attenuation coefficient for each type of tissue, future review of image quality comparison can be done focusing on specific tissue or region such as soft tissue, bone and lungs to reflect the real impact of CTAC and MRAC on PET image.

Keywords: PET/CT; PET/MR; attenuation correction; image quality

ABSTRAK

Kajian sistematik ini dijalankan untuk menilai kualiti imej apabila menggunakan data yang diperolehi daripada tomografi berkomputer (CTAC) atau resonans magnet untuk pembetulan pengecilan (MRAC) pada imej tomografi pancaran positron (PET). CTAC dan MRAC diaplikasi kepada imej yang diperolehi daripada pengimbas PET/CT dan PET/MR. Kajian sistematik dibuat berdasarkan Preferred Reporting Items for Systematic Reviews (PRISMA). Dalam kajian ini, dua belas artikel diperolehi daripada enam pangkalan data. Kualiti imej dinilai berdasarkan kualiti imej keseluruhan, kontras, resolusi ruang, kebolehdan, nilai serapan piawai (SUV) dan masa imbasan. Data ditunjukkan sebagai min \pm sisihan piawai dan dibandingkan antara imej CTAC dan MRAC untuk menentukan kaedah pembetulan pengecilan yang memberikan kualiti imej yang lebih baik. Keputusan mendapati kualiti imej PET-CTAC dan PET-MRAC adalah sama dari segi kualiti imej keseluruhan ($p=0.93$), pengesanan ($p=0.84$), SUV_{mean} ($p=0.84$) dan SUV_{max} ($p=0.81$). Sementara itu, masa imbasan PET-CTAC adalah dua kali lebih pantas berbanding PET-MRAC ($p < 0.05$). Tiada analisis statistik dilakukan untuk kontras imej, resolusi ruang dan nisbah kontras-bunyi kerana data yang tidak mencukupi. Kesimpulannya, walaupun prosedur imbasan PET/CT lebih pantas daripada PET/MRI, imej yang dihasilkan daripada CTAC dan MRAC adalah setara antara satu sama lain. Disebabkan pekali pengecilan linear berbeza untuk setiap jenis tisu, perbandingan kualiti imej boleh dilakukan pada masa hadapan dengan memfokuskan pada tisu atau rantau tertentu seperti tisu lembut, tulang dan paru-paru untuk menggambarkan kesan sebenar CTAC dan MRAC pada imej PET.

kata Kunci: PET/CT, PET/MR, pembetulan pengecilan, kualiti imej.

INTRODUCTION

Positron emission tomography (PET) is a diagnostic imaging method that allows observing organs' metabolic and physiologic processes in healthy and pathological states using radiopharmaceutical tracer. However, it cannot show anatomic features. The idea of having PET and computed tomography (CT) or magnetic resonance imaging (MRI) scanning led to hybrid scanners that combine the two modalities in one device. This hybrid imaging has given general advantages to medical imaging, such as increased diagnostic accuracy, precise monitoring of interventional procedures, and can reduce radiation exposure (Hicks et al. 2007). Generally, combination of both PET and CT scans would result in higher radiation dose due to internal exposure from PET and external irradiation of CT. However, this is not the case for PET/MRI where the radiation dose only comes from PET component. Indeed, the application of ultra-low dose technique has drastically decreased the CT radiation dose.

PET/MRI scan combine images from PET and MRI scans and it is beneficial in neuro-oncology, epilepsy, dementia syndromes, cerebrovascular disease, neurological disease, and psychiatric disorders (Miller-Thomas et al. 2017). They also detect malignancies in the neck and pelvis, among other organs. Combining these two modalities could produce great soft-tissue contrast, unique flexibility in acquisition parameters for characterising the tissue, and minimised exposure to radiation with enhanced sensitivity for desired clinical and research applications (Musafargani et al. 2018).

PET/CT is another modality to detect cancer and determine its stage. The stage indicates the original location of cancer or whether it has spread. It gives an advantage over anatomic imaging alone in cancer patients' initial staging and response assessment by combining functional and anatomic information (Fonti et al. 2019). Hence, doctors can plan and choose the best treatment by knowing the stages and location of cancer so that it makes the work easier to do the planning for the treatment.

PET imaging involved the two photons produced in collinearity during the decay of a positron-emitting radionuclide that must be detected within a predetermined time window to be counted as an actual coincidence event (Bailey et al. 2014). However, depending on the size of the body in the field of view, most photons are lost due to the photon-tissue interaction that causes absorption and scattering, which causes photon attenuation and leads to the loss of count detected. The higher density in bone makes the higher attenuation occur because of the higher

absorption in bone. In contrast, the tissue, which has a lower density than bone, causes low absorption, leading to lower attenuation (Bailey et al. 2005). Hence, appropriate data adjustments are required to obtain quantitative images that accurately reflect the radiotracer's actual spatial distribution. Plus, the data must be estimated based on known tissue types and their attenuation maps.

Attenuation correction is required to generate an accurate patient's specific attenuation mapping. This will lead to improve image quality and accuracy when interpreting images (Shukla et al. 2006). For example, CT attenuation correction has been shown to reduce PET image artefacts, improve specificity, and increase diagnostic certainty. Attenuation correction is vital for quantitative PET imaging as it can reduce artefacts by up to 90% (Chen et al. 2017). Hence, minor inaccuracies in identifying attenuation correction factors can lead to significant qualitative and quantitative diagnostic inaccuracies in PET images, including bias and artefacts.

By default, for the CTAC, PET image data captured with PET/CT scanners are adjusted for attenuation using CT image data (Visvikis et al. 2003). The image depends on tissues density and beams energy in which each image pixel is assigned to the corresponding CT numbers. The CT numbers in Hounsfield unit (HU) are then rescaled to a linear attenuation coefficient that matches the PET energy of 511 keV. The most common method of conversion uses a bilinear curve where a HU of -1,000 to 0 is classified as a mixture of soft tissue and air, and a HU greater than 0 is modeled as a mixture of soft tissue and bone (Kemp 2012). Although CTAC is often accurate, patient movement and the presence of CT contrast material may result in quantitative error and image artefacts. Respiratory motion generates discrepancies between the CTAC map and the actual attenuation during a PET scan, potentially leading to image artefacts (Chin et al. 2003).

Since the launch of the first clinical PET/MR machine in 2010 (Meikle et al. 2021), a variety of MR attenuation correction approaches have evolved and critical methodological improvements in the PET/MR field of neuroimaging (Teuho et al. (2020). Routinely in PET/MR scanning, the attenuation using MR data (MRAC) is related to the density of tissue. However, it is well-known that MRAC is not a direct process like CTAC since MRAC images represent proton density and tissue relaxation properties. Generally, several steps need to be performed in MRAC: segmenting the region based on corresponding attenuation properties, assigning a correct linear attenuation to each segmented area to produce an attenuation map, and using the map to correct the PET data during reconstruction (Wagenknecht et al. 2013). In addition, segmentation

strategies can be categorised into three types: manual image segmentation, atlas or database approaches which include machine learning methods, and emission data-driven approaches that use PET data alone or in conjunction with existing MRI data (Mecheter et al. 2020).

One advantage of PET/MR over PET/CT is the lower dose of ionising radiation delivered to patients because it is not associated with radiation for attenuation correction. It is found that the CT scan contributed between 32% to 79% of the total dose in PET/CT procedure (Adeleye et al. 2018). Also, the estimated mean effective dose for whole-body PET/MR results in a potential dose reduction of 79.6% compared to the PET/CT procedure (Martin et al. 2020). As in routine, CTAC and MRAC are implemented in PET/CT and PET/MRI images, respectively. Therefore, a systematic review was performed to investigate if PET/MR image also has superior image quality compared to PET/CT image, besides the advantage of its lower dose. Indirectly, we want to investigate which attenuation correction method, CTAC or MRAC, provides better image quality performance.

MATERIALS AND METHODS

SEARCH STRATEGY

This study utilised the systematic review protocol and methodology established by Preferred Reporting Items for Systematic Reviews and Meta-Analyses (PRISMA) (Page et al. 2021). The systematic literature search was carried out for articles published in six databases: PubMed, Scopus, Mendeley, Wiley, and EBSCOhost-MedlineComplete databases. The process involves the identification of keywords, screening the articles according to the inclusion and exclusion criteria, evaluating the article’s eligibility, and lastly, including articles for the systematic review.

The search keyword term method is based on Boolean Operators (Grewal et al. 2016), showing steps in planning the research study. The search strings used are shown in table 1; a search filter was used to limit the publication year (2016-2021), reflecting current improvement in modalities technique and widespread practice.

TABLE 1. Boolean operators and keyword search terms.

Resources	Search string
PUBMED	(PET/CT) AND (PET/MRI) AND attenuation correction AND image quality 5 years until present
SCOPUS	TITLE-ABS-KEY (pet/mri) AND TITLE-ABS-KEY (pet/ct) AND TITLE-ABS-KEY ITLE-ABS-KEY (image quality) AND PUBYEAR > 2015
MENDELEY	PET/MRI OR PET/CT /Attenuation correction/Image quality
Wiley	PET/CT OR PET/MRI AND Attenuation Correction OR Attenuation AND Image quality OR Factors
EBSCOhost-MedlineComplete	pet/ct pet/mr image resolution AND attenuation correction AND image quality AND SNR AND contrast AND spatial resolution

SELECTION CRITERIA

An initial screening of abstract identifications and titles was conducted by two reviewers (FN and MA) based on inclusion criteria developed using the patient/population, intervention, comparison and outcomes (PICO) method (Methley et al. 2014), shown in table 2. Studies excluded were those that did not relate to the outcome image quality of PET/CT and PET/MRI. Case study reports, summaries or review articles were also excluded. First, only the title

and abstract related to image quality between PET/CT and PET/MRI modalities were included for the full-text-review screening. After that, all the included full-text articles were examined thoroughly to ensure that they fulfilled the inclusion criteria of this current research (Xiao et al. 2017). A two-step method ensures that the articles will be screened wisely before extracting the data (Mathes et al. 2017). Papers were only included in the review if both reviewers agreed on them. A third reviewer was invited to appraise the paper for an overall agreement.

TABLE 2. PICO Method

Criteria	Indication
P-population	Phantom/ human/ animals study
I-intervention	CT-based and MR-based Attenuation Correction (AC)
C-comparison	Overall image quality; contrast, image resolution, detectability
O-outcome	Image quality will be measured

DATA REVIEW AND EXTRACTION PROTOCOL

Upon finalisation of the articles, both reviewers performed data extraction together. Information was extracted into spreadsheets, including title, authors, year of publication, population, and image quality metrics.

The measure of diagnostic image quality is based on quantitative and qualitative assessments (Abdullah et al. 2016). The evaluations for quantitative assessment were image contrast, spatial resolution, contrast-to-noise ratio (CNR), standardised uptake value (SUV); SUV_{max} and SUV_{mean} and acquisition time, whereas for the qualitative assessment were overall image quality scoring (Harpe 2015).

For overall image quality scoring, most of the studies used a 4-point Likert-type scale from 1 (poor) to 4 (excellent) (Kikuchi et al. 2021; Sawicki et al. 2016; Schwartz et al. 2018; Suzuki et al. 2021). Only one study used a 3-point Likert scale (Thomas et al. 2017) and a 5-point scale (Guberina et al. 2020), respectively. Due to varying scales, hence for statistical analysis, the scoring was normalised to a 5-point scale to ensure the data contribute equally to the analysis and avoid bias.

The overall image quality, resolution, and contrast descriptors were recorded in the mean ± SD range. However, for parameter detectability, the lesion’s detectability was stated as how many lesions were identified by image analysis after CTAC and MRAC.

STATISTICAL ANALYSIS

Statistical test was conducted using IBM SPSS Statistics 26.0. The result was presented as mean and standard deviation. The independent sample t-test and Mann-Whitney test were performed for normal and non-normal data distribution, respectively. The tests were done to compare whether there is any significant difference in image quality performance and quantitative data between CTAC and MRAC on PET images.

RESULTS

SEARCH RESULT

The flow chart performed in this study is shown in figure 1. Initially, the database system search returned a total of 505 citations. The removal of 198 duplicate articles resulted in 307 citations being identified that were relevant to the topic. From them, 182 citations were removed due to unrelated titles based on PICO, which resulted in 125 citations. Then, further removal of 95 citations was performed as the abstracts were not related based on PICO and review articles. The remaining 30 citations were filtered, and 16 articles were removed due to not enough data provided in the articles regarding image quality and the outcome of the studies. This yielded 14 citations to be included in the review. Two citations were further excluded as they did not provide enough data to compare the two modalities.

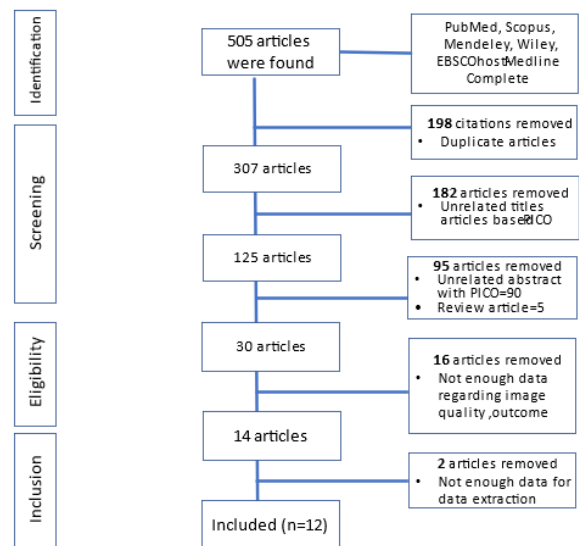


FIGURE 1. PRISMA Flow Chart

CHARACTERISTICS OF SELECTED STUDIES

The 12 articles selected consisted of nine articles that performed on human, two articles on phantom and one article involved human and phantom. Of these, the ten studies recruited a total sample size of 392 patients. While three articles did not provide the details of gender, the total male and female samples from nine articles were 123, respectively. In addition, eight articles provided the sample range age between 5-88 years old and four articles did not state the sample range age.

The summary of image quality metrics such as overall image quality, contrast, spatial resolution, contrast-noise-ratio (CNR) and detectability on human and phantom were exhibited in Tables 3 and 4, respectively.

From now on, the PET image with CT and MR attenuation correction is referred as PET-CTAC and PET-MRAC, respectively. Overall image quality data for PET-CTAC and PET-MRAC for human studies are shown in table 3. However, no respective data was provided for the phantom study as shown in Table 4.

A total of 713 lesions were detected on PET-CTAC and 679 on PET-MRAC images in human studies as shown in table 3 (Demir et al. 2018; Fraum et al. 2016; Guberina et al. 2020; Kikuchi et al. 2021; Knešaurek et al. 2018; Liu et al. 2019; Øen et al. 2019; Poirier et al. 2021; Sawicki et al. 2016; Schwartz et al. 2018; Suzuki et al. 2021; Thomas et al. 2017). Most of the lesions were not observed in PET-MRAC images due to low SUVs and artefacts that interrupt the image production (Thomas et al. 2017).

For phantom studies in Table 4, (Demir et al. 2018) demonstrated that contrast value for different sizes of hot spheres for PET-MRAC image was approximately 9% higher than PET-CTAC. Also, the axial spatial resolution for PET-MRAC was higher than PET-CTAC. However, the PET-MRAC transverse spatial resolution was lower than PET-CTAC. In addition, study from (Øen et al. 2019) found that PET-CTAC has better detectability than PET-MRAC in the same activity concentration.

TABLE 3. Image quality measurements on human studies

Authors	Overall Image Quality	Contrast	Spatial resolution	CNR	Detectability
(Thomas et al. 2017)	PET/CT= 2.9 ± 0.3 PET/MRI= 2.6 ± 0.5	NS	NS	NS	PET/CT=112 PET/MRI=108
(Poirier et al. 2021)	NS	NS	NS	NS	NS
(Knešaurek et al. 2018)	NS	NS	Transverse PET/CT=4.5 PET/MRI=4.2 Axial PET/CT=4.7 PET/ MRI=4.6	NS	NS
(Sawicki et al. 2016)	PET/CT= 3.7 ± 0.5 PET/MRI= 3.5 ± 0.5	NS	NS	NS	PET/CT= 241 PET/MRI= 161
(Liu et al. 2019)	NS	NS	NS	NS	PET/CT=15/26 PET/MRI=20/26
(Fraum et al. 2016)	NS	NS	NS	NS	PET/CT=35/50 (70%) PET/MRI=40/50 (80%)
(Kikuchi et al. 2021)	PET/CT= 2.0 ± 1.1 PET/MRI= 2.8 ± 1.2	NS	NS	NS	PET/CT= 92 PET/MRI= 123
(Suzuki et al. 2021)	PET/CT Average Score= 3 PET/MRI Average Score=2.14	PET/CT Average Score=3.1 PET/MRI Score =1	NS	NS	PET/CT=13 PET/MRI=12
(Schwartz et al. 2018)	Average score PET/MRI=4 PET/CT=4		NS		PRIMARY TUMOR PET/MRI=17/17 PET/CT=17/17 REGIONAL LYMPH NODES

continue...

...cont.

						PET/MRI=26 PET/CT=26 ABDOMINAL METS PET/MRI=6 PET/CT=6 DISTANT METS PET/MRI=0 PET/CT=6 SOFT TISSUE INVASION PET/MRI=7 PET/CT=0
Guberina et al. (2020)	PET/CT=4.8 PET/MRI=4.7	PET/CT=5.0 PET/MRI=4.7	NS	NS		PET/CT=150 PET/MRI=159

NS=Not Stated; PET/MRI=Positron emission tomography–magnetic resonance imaging; PET/CT=Positron Emission Tomography -Computed Tomography; Mets= Metastasis; CNR=contrast-noise-ratio

TABLE 4. Image quality measurements on phantom studies

Authors	Overall image quality	Contrast	Spatial resolution	CNR	Detectability
(Knešaurek et al. 2018)	NS	NS	NS	NS	NS
(Demir et al. 2018)	NS	-PET/CT 10mm-30% 13mm-35% 17mm-45% 22mm-55% -PET/MR 10mm-56% 13mm-72% 17mm-78% 22mm-85% PET/MR was ~ 9% higher than PET/CT	Transverse PET/CT=4.73, PET/MRI=4.3 Axial PET/CT=4.93, PET/MRI=5.79	NS	NS
(Øen et al. 2019)	NS	NS	NS	PET/CT=5.1 PET/MRI=5.8	6-mm sphere - the smallest detected sphere with PET/MRI 5-mm sphere was detected with PET/CT in the 8:1 activity concentration

NS=Not Stated; PET/MRI=Positron emission tomography–magnetic resonance imaging; PET/CT=Positron Emission Tomography -Computed Tomography; Mets= Metastasis; CNR=contrast-noise-ratio

Table 5 shows quantitative parameters which include SUVmean, SUVmax and acquisition time. A total of six studies obtained acquisition time data (Fraum et al. 2016; Guberina et al. 2020; Sawicki et al. 2016; Schwartz et al. 2018; Suzuki et al. 2021; Thomas et al. 2017), five studies

provided SUVmean (Demir et al. 2018; Kikuchi et al. 2021; Knešaurek et al. 2018; Øen et al. 2019; Poirier et al. 2021) and seven studies provided SUVmax data (Fraum et al. 2016; Guberina et al. 2020; Liu et al. 2019; Sawicki et al. 2016; Schwartz et al. 2018; Suzuki et al. 2021; Thomas et al. 2017).

TABLE 5. Quantitative parameters

Authors	Mean SUVmax	Mean SUVmean	Acquisition Time
(Thomas et al. 2017)	PET/CT=5.3 ± 2.4 PET/MRI=4.3 ± 2.5	PET/CT=3.5 ± 1.5 PET/MRI=2.6 ± 1.4	PET/CT=89.1 ± 29.9 PET/MR=79.5 ± 17.4 min
(Poirier et al. 2021)	NS	PET/CT=8.43 ± 2.23 PET/MRI=8.08 ± 2.17	NS
(Sawicki et al. 2016)	PET/CT= 6.09 ± 6.5 PET/MRI=7.39 ± 6.7	PET/CT=3.3 ± 2.9 PET/MRI=3.73 ± 2.9	PET/CT= 61 ± 10.3 min PET/MRI=(113.9 ± 28.5)
(Liu et al. 2019)	PET CT=7.95 PETMRI=7.14	NS	NS
(Fraum et al. 2016)	PET/CT=7.5 ± 3.8 PET/MRI=7.0 ± 4.0	PET/CT=4.3 ± 1.8 PET/MRI=4.0 ± 2.0	PET/CT=62 ± 15 min PET/MRI=127 ± 16 min
(Suzuki et al. 2021)	PET/CT=5.81 ± 2.62 PET/MRI=8.46 ± 3.12	PET/CT=3.33 ± 1.73 PET/MRI=5.11±2.21	PET/CT= 21–73 min PET/MRI= 83–136 min
Schwartz et al. (2018)	PET/MRI=16.5±7.1 PET/CT=21.5±10.8	NS	PET/CT= 55min PET/MRI= 110 min
Guberina et al. (2020)	PET/MRI=24.1 PET/CT=15.1	NS	PET/CT= 20min PET/MRI= 70 min

NS=Not Stated; PET/MRI=Positron emission tomography–magnetic resonance imaging; PET/CT=Positron Emission Tomography -Computed Tomography; Mets= Metastasis; CNR=contrast-noise-ratio

STATISTICAL RESULTS

Table 6 shows the statistical results for the data collected. It is concluded that there are no significant differences in overall image quality, detectability, SUVmean and

SUVmax between PET-CTAC and PET-MRAC images. Meanwhile, PET-CTAC acquisition time is significantly faster than and PET-MRAC by approximately twofold. No statistical analyses were performed for image contrast, spatial resolution and CNR due to insufficient data.

TABLE 6. Statistical analysis on image quality and quantitative parameters

Parameters	Mean±SD		P value
	PET-CTAC	PET-MRAC	
Overall Image Quality (n=6)	4.46 ± 0.97	4.95 ± 1.13	0.93
Image Contrast (n=2)	4.05 ± 1.34	2.85 ± 2 .62	-
Spatial Resolution (n=1)	Transverse= 4.62 ± 0.16 Axial= 4.82 ± 0.16	Transverse= 4.25 ± 0.07 Axial= 5.20 ± 0.84	-
Contrast-Noise-Ratio (CNR)(n=1)	5.1	5.8	-
Detectability (n=8)	59.42 ± 75.00	56.58 ± 62.35	0.84
SUVmean (n=5)	4.57 ± 2.19	4.70 ± 2.09	0.84

continue...

...cont.

SUVmax (n=7)	9.67 ± 5.91	10.71 ± 7.06	0.81
Acquisition Time (n=6)	60.02 ± 23.00 min	106.01 ± 26.14 min	0.01*

n= # of articles, PET/MRI=Positron emission tomography–magnetic resonance imaging; PET/CT=Positron Emission Tomography -Computed Tomography; SUV=Standardized Uptake Value, * = significant.

DISCUSSION

This systematic review compared image quality performance produced by CT and MR attenuation correction on PET images. It also determines the advantages and disadvantages of PET/CT and PET/MRI that are used for various treatment options.

Statistically, the overall image quality performance between PET-CTAC and PET-MRAC are equivalent to each other. However, the overall image quality of PET-MRAC is lower than PET-CTAC due to image artefacts caused by patient's motion, respiration, or peristalsis internal organ motion and has a longer acquisition time compared to PET/CT (Liu et al. 2019; Thomas et al. 2017). This problem can probably be encountered using a breath-hold (HASTE and VIBE). But not all patients can comply with this technique especially patients who have a lung-related disease such as tuberculosis (Thomas et al. 2017). In addition, the overall image quality metrics used in previous studies did not measure the diagnostic quality of the image whether it changed the prognosis and patient management. Hence, there is no conclusion can be made regarding the capabilities of CTAC and MRAC in improving the diagnosis.

A total of 713 lesions have been detected by PET-CTAC image compared to 679 by PET-MRAC image in all studies. PET/CT is superior in detecting more abnormal lesions compared to PET/MRI, thus continuing to be the gold standard for determining the TNM stage (Liu et al. 2019). Although the result showed that no significant difference in both modalities in detecting lesions, it was found that PET-MRAC image tends to miss lesion less than 10 mm size, particularly in the lung area (Sawicki et al. 2016). In contrast, PET-MRAC image was capable to detect lesion in soft-tissue compared to PET-CTAC. It was found that PET-MRAC can detect one cancer with soft tissue disease involvement, but it was not detected on the PET-CTAC image (Schwartz et al. 2018). Also, PET-MRAC offers high-resolution anatomic data on images and performs better than PET-CTAC image in T3 staging at abdominal area (Liu et al. 2019). Other than that, PET-MRAC was found to have higher diagnostic accuracy than PET-CTAC image in locating the Epileptogenic zone in patients with focal epilepsy (Kikuchi et al. 2021) and detecting recurrence of prostate cancer (Guberina et al. 2020).

SUVmean and SUVmax are useful while accessing F-18 FDG (fluorodeoxyglucose) uptake to detect tumour activity and the prognosis of the lesion. However, it may be less helpful in detecting tumour's extension (Fardin et al. 2016). This systematic review confirmed that PET-MRAC has slightly higher SUVmax at the soft-tissue area such as on the whole body, lung, and brain region compared to PET-CTAC (Guberina et al. 2020; Sawicki et al. 2016; Suzuki et al. 2021). However, the uptake difference was not significant. In all 12 studies using F-18 FDG as a radiotracer, the acquisition time after injection FDG was found to significantly affect overall SUVs value. In most of the articles, PET/MRI was acquired after the PET/CT imaging (Fraum et al. 2016; Guberina et al. 2020; Kikuchi et al. 2021; Liu et al. 2019; Sawicki et al. 2016; Schwartz et al. 2018; Suzuki et al. 2021; Thomas et al. 2017). The differences observed between PET-MRAC and PET-CTAC SUV values may be due to the time delay in acquisition time between PET/CT scans and PET/MRI scans or the biological clearance of the radiotracer (Kershah et al. 2013). This should be taken into consideration since, some SUVs values for PET-MRAC image were higher but some were lower than PET-CTAC image. So, these observations would suggest why the variations in SUVs values between PET-CTAC and PET-MRAC images occurred and may be a systematic error between both modalities data.

The acquisition time for PET/MRI is significantly longer compared to PET/CT imaging by two-fold. Some studies have suggested further dose reduction while injecting radiotracer procedure in PET/MRI, prolonging the acquisition time since the MRI procedure takes a very long time to finish (Oehmigen et al. 2014). This had to be taken into consideration to be in the future research.

Our retrospective study has some limitations. First, we only compare the overall data from many regions in the body and did not focus on a specific region. Hence, there is bias in the statistical analysis since the data may be come lots from one region only and lead to overestimate or underestimate the result. The data was limited to several regions: the brain, lung, gastric, and whole body. Thus, the comparison between PET-CTAC and PET-MRAC image quality is restricted to only those regions. A second limitation was that we did not consider the PET/CT protocols and PET/MR sequences used. PET/CT was widely available and had established imaging protocols as compared to PET/MR which has limited availability, and

its protocols were still in development. Moreover, various PET/MR sequences such as spin echo and gradient echo has some effect on the overall image quality. MR sequences are wave forms of the gradients and radiofrequency pulses applied in MR image acquisition. In terms of reducing magnetic inhomogeneity, spin echo sequence was more efficient than gradient echo, thus will affect the image quality produced (Bitar et al. 2006).

CONCLUSION

This study has shown that image quality is comparable between PET-CTAC and PET-MRAC images concerning their advantages and disadvantages. It can no longer be denied that PET/MRI offers the advantages of reduced radiation exposure to patients, as radiation might have long-term side effects in the future. Other than that, PET/MRI can also differentiate and classify better soft tissue lesions than PET/CT as it offers high-resolution anatomic data on images and performs better than PET/CT in advanced staging. On the contrary, PET/CT also have advantages such as a shorter acquisition time and still being maintained as the gold standard for determining the TNM stage due to its high sensitivity in detecting abnormal lesions.

Declaration of interest: none

REFERENCES

- Abdullah, K. A., McEntee, M. F., Reed, W. & Kench, P. L. 2016. Radiation dose and diagnostic image quality associated with iterative reconstruction in coronary CT angiography: A systematic review. *J Med Imaging Radiat Oncol* 60(4): 459-468.
- Adeleye, B. & Chetty, N. 2018. Radiation dose from 18F-FDG PET/CT procedures: Influence of specific CT model and protocols. *Radioprotection* 53(2): 107-113.
- Bailey, D. L., Humm, J. L., Tod-Pokropek, A. & Van Aswegen, A. 2014. Nuclear Medicine Imaging Devices. Dlm. *Nuclear Medicine Physics A Handbook for Teachers and Students*, 312. Vienna, Austria: International Atomic Energy Agency (IAEA).
- Bailey, D. L., Karp, J. S. & Surti, S. 2005. Physics and Instrumentation in PET. Dlm. Bailey, D. L., Townsend, D. W., Valk, P. E. & Maisey, M. N. Dlm. *Positron Emission Tomography: Basic Sciences*, 13-39. London: Springer London.
- Bitar, R., Leung, G., Perng, R., Tadros, S., Moody, A. R., Sarrazin, J., McGregor, C., Christakis, M., Symons, S., Nelson, A. & Roberts, T. P. 2006. MR Pulse Sequences: What Every Radiologist Wants to Know but Is Afraid to Ask. *Radiographics* 26(2): 513-537.
- Chen, K. T., Izquierdo-Garcia, D., Poynton, C. B., Chonde, D. B. & Catana, C. 2017. On the accuracy and reproducibility of a novel probabilistic atlas-based generation for calculation of head attenuation maps on integrated PET/MR scanners. *European Journal of Nuclear Medicine and Molecular Imaging* 44(3): 398-407.
- Chin, B., Nakamoto, Y., Kraitchman, D., Marshall, L. & Wahl, R. 2003. Chin BB, Nakamoto Y, Kraitchman DL, Marshall L, Wahl R. PET-CT evaluation of 2-deoxy-2-[18F]fluoro-D-glucose myocardial uptake: Effect of respiratory motion. *Molecular imaging and biology : MIB : The official publication of the Academy of Molecular Imaging* 5: 57-64.
- Demir, M., Toklu, T., Abuqbeith, M., Çetin, H., Sezgin, H. S., Yeyin, N. & Sönmezoğlu, K. 2018. Evaluation of PET Scanner Performance in PET/MR and PET/CT Systems: NEMA Tests. *PET/MR ve PET/CT Sistemlerinde PET Tarayıcının Performanslarının Değerlendirilmesi: NEMA Testleri*. 27(1): 10-18.
- Fardin, S., Gholami, S., Werner, T. J., Rook, A. H. & Alavi, A. 2016. Chapter 35 - Imaging Evaluation of Cutaneous Lymphoma Using Functional and Structural Imaging. Dlm. *Imaging in Dermatology*, edited by Hamblin, M. R., Avci, P. & Gupta, G. K., 485-490. Boston: Academic Press.
- Fonti, R., Conson, M. & Del Vecchio, S. 2019. PET/CT in radiation oncology. *Semin Oncol* 46(3): 202-209.
- Fraum, T. J., Fowler, K. J. & McConathy, J. 2016. Conspicuity of FDG-Avid Osseous Lesions on PET/MRI Versus PET/CT: A Quantitative and Visual Analysis. *Nuclear Medicine and Molecular Imaging* 50(3): 228-239.
- Grewal, A., Kataria, H. & Dhawan, I. 2016. Literature search for research planning and identification of research problem. *Indian Journal of Anaesthesia* 60(9): 635-639.
- Guberina, N., Hetkamp, P., Ruebben, H., Fendler, W., Grueneisen, J., Suntharalingam, S., Kirchner, J., Puellen, L., Harke, N., Radtke, J. P., Umutlu, L., Hadaschik, B. A., Herrmann, K., Forsting, M. & Wetter, A. 2020. Whole-Body Integrated [68Ga] PSMA-11-PET/MR Imaging in Patients with Recurrent Prostate Cancer: Comparison with Whole-Body PET/CT as the Standard of Reference. *Molecular Imaging and Biology* 22(3): 788-796.
- Harpe, S. E. 2015. How to analyze Likert and other rating scale data. *Currents in Pharmacy Teaching and Learning* 7(6): 836-850.

- Hicks, R., Lau, E. & Binns, D. 2007. Hybrid imaging is the future of molecular imaging. *Biomedical Imaging and Intervention Journal* 3(3): e49-e49.
- Kemp, B. 2012. PET Physics and Instrumentation. Dlm. *PET-CT and PET-MRI in Oncology: A Practical Guide*, edited by Peller, P., Subramaniam, R. & Guermazi, A., 3-17. Berlin, Heidelberg: Springer Berlin Heidelberg.
- Kershah, S., Partovi, S., Traughber, B. J., Muzic, R. F., Jr., Schluchter, M. D., O'donnell, J. K. & Faulhaber, P. 2013. Comparison of standardized uptake values in normal structures between PET/CT and PET/MRI in an oncology patient population. *Molecular Imaging and Biology* 15(6): 776-785.
- Kikuchi, K., Togao, O., Yamashita, K., Momosaka, D., Nakayama, T., Kitamura, Y., Kikuchi, Y., Baba, S., Sagiya, K., Ishimatsu, K., Kamei, R., Mukae, N., Iihara, K., Suzuki, S. O., Iwaki, T. & Hiwatashi, A. 2021. Diagnostic accuracy for the epileptogenic zone detection in focal epilepsy could be higher in FDG-PET/MRI than in FDG-PET/CT. *European Radiology* 31(5): 2915-2922.
- Knešaurek, K., Tuli, A., Kim, E., Heiba, S. & Kostakoglu, L. 2018. Comparison of PET/CT and PET/MR imaging and dosimetry of yttrium-90 (90Y) in patients with unresectable hepatic tumors who have received intra-arterial radioembolization therapy with 90Y microspheres. *EJNMMI Physics* 5(1).
- Liu, Y., Zheng, D., Liu, J. J., Cui, J. X., Xi, H. Q., Zhang, K. C., Huang, X. H., Wei, B., Wang, X. X., Xu, B. X., Li, K., Gao, Y. H., Liang, W. Q., Tian, J. H. & Chen, L. 2019. Comparing PET/MRI with PET/CT for Pretreatment Staging of Gastric Cancer. *Gastroenterol Res Pract* 2019(9564627).
- Martin, O., Schaarschmidt, B. M., Kirchner, J., Suntharalingam, S., Grueneisen, J., Demircioglu, A., Heusch, P., Quick, H. H., Forsting, M., Antoch, G., Herrmann, K. & Umutlu, L. 2020. PET/MRI Versus PET/CT for Whole-Body Staging: Results from a Single-Center Observational Study on 1,003 Sequential Examinations. *J Nucl Med* 61(8): 1131-1136.
- Mathes, T., Klaben, P. & Pieper, D. 2017. Frequency of data extraction errors and methods to increase data extraction quality: A methodological review. *BMC medical research methodology* 17(1): 152-152.
- Mecheter, I., Alic, L., Abbod, M., Amira, A. & Ji, J. 2020. MR Image-Based Attenuation Correction of Brain PET Imaging: Review of Literature on Machine Learning Approaches for Segmentation. *Journal of Digital Imaging* 33(5): 1224-1241.
- Meikle, S. R., Sossi, V., Roncali, E., Cherry, S. R., Banati, R., Mankoff, D., Jones, T., James, M., Sutcliffe, J., Ouyang, J., Petibon, Y., Ma, C., El Fakhri, G., Surti, S., Karp, J. S., Badawi, R. D., Yamaya, T., Akamatsu, G., Schramm, G., Rezaei, A., Nuyts, J., Fulton, R., Kyme, A., Lois, C., Sari, H., Price, J., Boellaard, R., Jeraj, R., Bailey, D. L., Eslick, E., Willowson, K. P. & Dutta, J. 2021. Quantitative PET in the 2020s: A roadmap. *Physics in medicine & biology* 66(6): 06RM01-06RM01.
- Methley, A. M., Campbell, S., Chew-Graham, C., McNally, R. & Cheraghi-Sohi, S. 2014. PICO, PICOS and SPIDER: A comparison study of specificity and sensitivity in three search tools for qualitative systematic reviews. *BMC health services research* 14(579-579).
- Miller-Thomas, M. M. & Benzinger, T. L. 2017. Neurologic Applications of PET/MR Imaging. *Magnetic resonance imaging clinics of North America* 25(2): 297-313.
- Musafargani, S., Ghosh, K. K., Mishra, S., Mahalakshmi, P., Padmanabhan, P. & Gulyás, B. 2018. PET/MRI: A frontier in era of complementary hybrid imaging. *Eur J Hybrid Imaging* 2(1): 12.
- Oehmigen, M., Ziegler, S., Jakoby, B. W., Georgi, J. C., Paulus, D. H. & Quick, H. H. 2014. Radiotracer dose reduction in integrated PET/MR: Implications from national electrical manufacturers association phantom studies. *J Nucl Med* 55(8): 1361-1367.
- Øen, S. K., Aasheim, L. B., Eikenes, L. & Karlberg, A. M. 2019. Image quality and detectability in Siemens Biograph PET/MRI and PET/CT systems—a phantom study. *EJNMMI Physics* 6(1): 1-10.
- Page, M. J., McKenzie, J. E., Bossuyt, P. M., Boutron, I., Hoffmann, T. C., Mulrow, C. D., Shamseer, L., Tetzlaff, J. M., Akl, E. A., Brennan, S. E., Chou, R., Glanville, J., Grimshaw, J. M., Hróbjartsson, A., Lalu, M. M., Li, T., Loder, E. W., Mayo-Wilson, E., McDonald, S., McGuinness, L. A., Stewart, L. A., Thomas, J., Tricco, A. C., Welch, V. A., Whiting, P. & Moher, D. 2021. The PRISMA 2020 statement: An updated guideline for reporting systematic reviews. *BMJ* 372(71).
- Poirier, S. E., Kwan, B. Y. M., Jurkiewicz, M. T., Samargandy, L., Iacobelli, M., Steven, D. A., Lam Shin Cheung, V., Moran, G., Prato, F. S., Thompson, R. T., Burneo, J. G., Anazodo, U. C. & Thiessen, J. D. 2021. An evaluation of the diagnostic equivalence of 18F-FDG-PET between hybrid PET/MRI and PET/CT in drug-resistant epilepsy: A pilot study. *Epilepsy Research* 172.
- Sawicki, L. M., Grueneisen, J., Buchbender, C., Schaarschmidt, B. M., Gomez, B., Ruhlmann, V., Wetter, A., Umutlu, L., Antoch, G. & Heusch, P. 2016. Comparative Performance of ¹⁸F-FDG PET/MRI and ¹⁸F-FDG PET/CT in Detection and Characterization of Pulmonary Lesions in 121 Oncologic Patients. *J Nucl Med* 57(4): 582-586.
- Schwartz, M., Gavane, S. C., Bou-Ayache, J., Kolev, V., Zakashansky, K., Prasad-Hayes, M., Taouli, B., Chuang, L. & Kostakoglu, L. 2018. Feasibility and diagnostic performance of hybrid pet/mri compared with pet/ct for gynecological

- malignancies: A prospective pilot study. *Abdominal Radiology* 43(12): 3462-3467.
- Shukla, A. K. & Kumar, U. 2006. Positron emission tomography: An overview. *J Med Phys* 31(1): 13-21.
- Suzuki, M., Fushimi, Y., Okada, T., Hinoda, T., Nakamoto, R., Arakawa, Y., Sawamoto, N., Togashi, K. & Nakamoto, Y. 2021. Quantitative and qualitative evaluation of sequential PET/MRI using a newly developed mobile PET system for brain imaging. *Japanese Journal of Radiology* 39(7): 669-680.
- Teuho, J., Torrado-Carvajal, A., Herzog, H., Anazodo, U., Klén, R., Iida, H. & Teräs, M. 2020. Magnetic Resonance-Based Attenuation Correction and Scatter Correction in Neurological Positron Emission Tomography/Magnetic Resonance Imaging—Current Status With Emerging Applications. *Frontiers in Physics* 7(243):
- Thomas, B. A., Molton, J. S., Leek, F., Pang, Y., Totman, J. J., Paton, N. I. & Townsend, D. W. 2017. A comparison of 18F-FDG PET/MR with PET/CT in pulmonary tuberculosis. *Nuclear Medicine Communications* 38(11): 971-978.
- Visvikis, D., Costa, D. C., Croasdale, I., Lonn, A. H., Bomanji, J., Gacinovic, S. & Ell, P. J. 2003. CT-based attenuation correction in the calculation of semi-quantitative indices of [18F]FDG uptake in PET. *Eur J Nucl Med Mol Imaging* 30(3): 344-353.
- Wagenknecht, G., Kaiser, H. J., Mottaghy, F. M. & Herzog, H. 2013. MRI for attenuation correction in PET: Methods and challenges. *Magma*. 26 (1): 99-113. [Feb].
- Xiao, Y. & Watson, M. 2017. Guidance on Conducting a Systematic Literature Review. *Journal of Planning Education and Research* 39(1): 93-112.

Rukiah A Latiff
 Mohd Izuan Ibrahim
 Centre of Diagnostic, Therapeutic and Investigative Studies,
 Faculty of Health Sciences,
 The National University of Malaysia

Mohammad Aizart Rosli
 Nur Farhana Najwa ELYas Yeow
 Diagnostic Imaging and Radiotherapy Programme,
 Faculty of Health Sciences,
 The National University of Malaysia.

Corresponding: Rukiah A. Latiff (PhD)

Email: rukiah@ukm.edu.my